

United States Navy

Hospital Corpsman
NAVEDTRA 14295

Chapter 1 Anatomy and
Physiology

<http://www.survivalprimer.com/>

paul@survivalprimer.com

CHAPTER 1

ANATOMY AND PHYSIOLOGY

Knowledge of how the human body is constructed and how it works is an important part of the training of everyone concerned with healing the sick or managing conditions following injury. This chapter will provide you with a general knowledge of the structures and functions of the body.

The human body is a combination of organ systems, with a supporting framework of muscles and bones and an external covering of skin. The study of the body is divided into three sciences:

Anatomy—the study of body structures and the relation of one part to another.

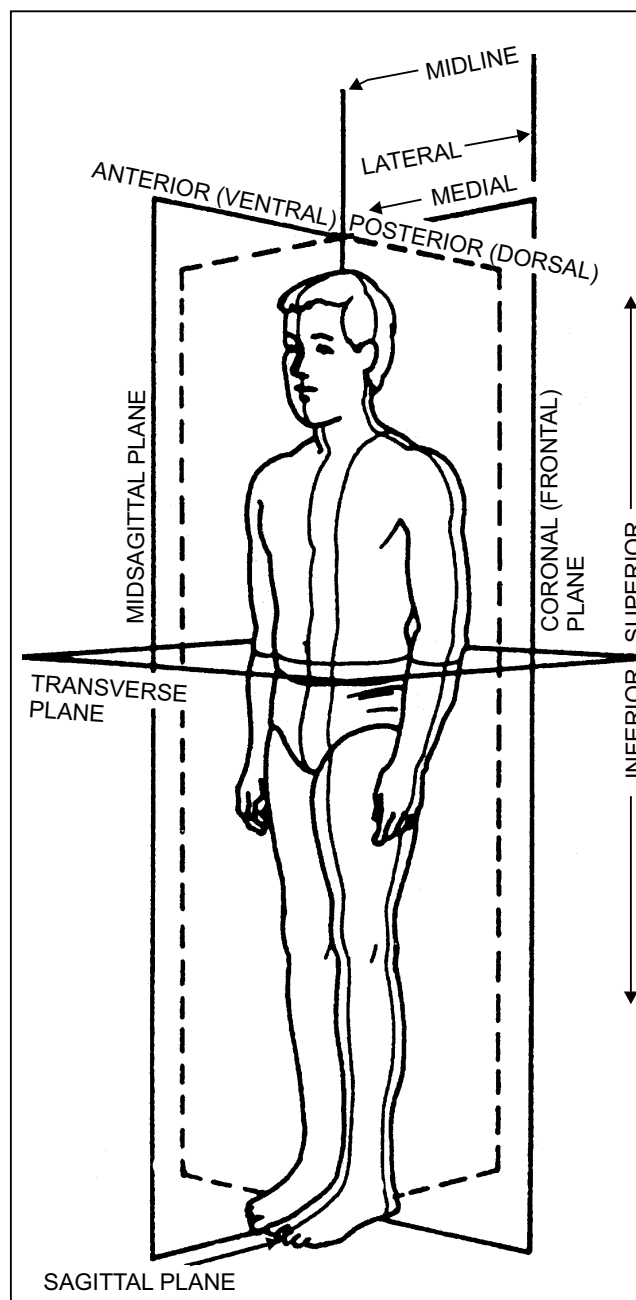
Physiology—the study of the processes and functions of the body tissue and organs. Physiology is the study of how the body works and how the various parts function individually and in relation to each other.

Embryology—the study of the development of the body from a fertilized egg, or ovum.

TERMS OF POSITION AND DIRECTION

LEARNING OBJECTIVE: *Identify anatomical terms of position and direction.*

The planes of the body are imaginary lines dividing it into sections. These planes are used as reference points in locating anatomical structures. As shown in figure 1-1, the **median**, or **midsagittal**, **plane** divides the body into right and left halves on its vertical axis. This plane passes through the sagittal suture of the cranium; therefore, any plane parallel to it is called a **sagittal plane**. **Frontal planes** are drawn perpendicular to the sagittal lines and divide the body into anterior (front) and posterior (rear) sections. Since this line passes through the coronal suture of the cranium, frontal planes are also called **coronal planes**. The **horizontal**, or **transverse**, **plane**, which is drawn at right angles to both sagittal and frontal planes, divides the body into superior (upper) and inferior (lower) sections.



HM3F0101

Figure 1-1.—Planes of the body.

To aid in understanding the location of anatomical structures, you should use a standard body position called the **anatomical position** as a point of reference. This anatomical position is assumed when the body

stands erect with the arms hanging at the sides and the palms of the hands turned forward (fig. 1-2).

Other commonly used anatomical terms include the following:

Anterior or ventral—toward the front, or ventral (pertaining to the belly; abdomen), side of the body.

Posterior or dorsal—toward the back, or rear, side of the body.

Medial—near or toward the midline of the body.

Lateral—farther away from the midline of the body.

Internal—inside.

External—outside.

Proximal—nearer the point of origin or closer to the body.

Distal—away from the point of origin or away from the body.

Superior—higher than or above.

Cranial—toward the head.

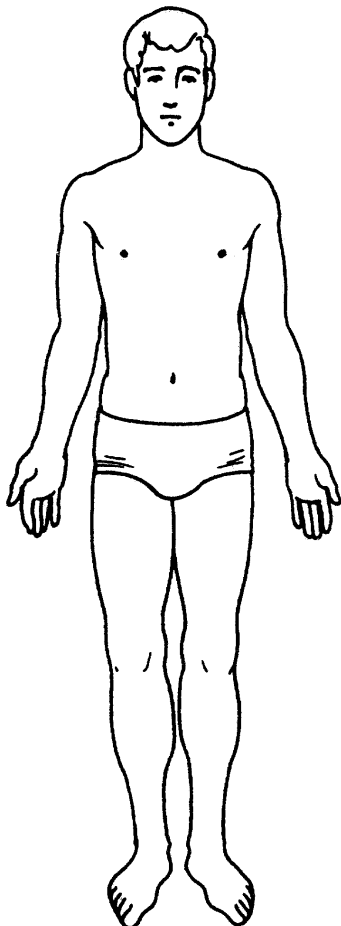


Figure 1-2.—Anatomical position.

Caudal—toward the lower end of the body.

Inferior—lower than or below.

Erect—normal standing position of the body.

Supine—lying position of the body, face up.

Prone—lying position of the body, face down.

Lateral recumbent—lying position of the body on either side.

Peripheral—the outward part or surface of a structure.

CHARACTERISTICS OF LIVING MATTER

LEARNING OBJECTIVE: *Identify the characteristics of living matter.*

All living things, animals and plants, are organisms that undergo chemical processes by which they sustain life and regenerate cells. The difference between animals and plants is that animals have sensations and the power of voluntary movement, and they require oxygen and organic food. On the other hand, plants require only carbon dioxide and inorganic matter for food and have neither voluntary movement nor special sensory organs.

In man, some of the characteristic functions necessary for survival include **digestion**, **metabolism**, and **homeostasis**. Digestion involves the physical and chemical breakdown of the food we eat into its simplest forms. Metabolism is the process of absorption, storage, and use of these foods for body growth, maintenance, and repair. Homeostasis is the body's self-regulated control of its internal environment. It allows the organism to maintain a state of constancy or equilibrium, in spite of vast changes in the external environment.

THE CELL

LEARNING OBJECTIVE: *Identify the parts of the cell and their functions.*

The cell, the smallest unit of life, is the basic structural unit of all living things and a functional unit all by itself. Cells are composed of a viscid, jellylike substance, called **protoplasm**, upon which depend all the vital functions of nutrition, secretion, growth,

circulation, reproduction, excitability, and movement. Protoplasm, thus, has often been called “the secret of life.”

A typical cell is made up of the plasma membrane, the nucleus, and the cytoplasm.

The **plasma membrane** is a selectively permeable membrane surrounding the cell. In addition to holding the cell together, the membrane selectively controls the exchange of materials between the cell and its environment by physical and chemical means. Gases (such as oxygen) and solids (such as proteins, carbohydrates, and mineral salts) pass through the plasma membrane by a process known as **diffusion**.

The **nucleus** is a small, dense, usually spherical body that controls the chemical reactions occurring in the cell. The substance contained in the nucleus is called **nucleoplasm**. The nucleus is also important in the cell's reproduction, since genetic information for the cell is stored there. Every human cell contains 46 chromosomes, and each chromosome has thousands of genes that determine the cell's function.

The **cytoplasm** is a gelatinous substance surrounding the nucleus and is contained by the plasma membrane. The cytoplasm is composed of all of the cell protoplasm except the nucleus.

The simplest living organism consists of a single cell. The amoeba is a unicellular animal. The single cell of such a one-celled organism must be able to carry on all processes necessary for life. This cell is called a **simple** or **undifferentiated cell**, one that has not acquired distinguishing characteristics.

In multicellular organisms, cells vary in size, shape, and number of nuclei. When stained, the various cell structures can be more readily recognized under a microscope. Other differences such as the number and type of cells can be seen with the aid of a microscope. Many cells are highly specialized. **Specialized cells** perform special functions (e.g., muscle cells, which contract, and epithelial cells, which protect the skin).

TISSUES

LEARNING OBJECTIVES: *Identify the types of tissues in the human body and their functions.*

Tissues are groups of specialized cells similar in structure and function. They are classified into four

main groups: epithelial, connective, muscular, and nervous.

EPITHELIAL TISSUE

The lining tissue of the body is called **epithelium**. It forms the outer covering of the body known as the free surface of the skin. It also forms the lining of the digestive, respiratory, and urinary tracts; blood and lymph vessels; serous cavities (cavities which have no communication with the outside of the body, and whose lining membrane secretes a serous fluid), such as the peritoneum or pericardium; and tubules (small tubes which convey fluids) of certain secretory glands, such as the liver and kidneys. Epithelial tissues are classified according to their shape, arrangement, and the function of their cells. For example, epithelial tissues that are composed of single layers of cells are called “simple,” while cells with many layers are said to be “stratified.” In the following paragraphs we will discuss the three categories of epithelial tissue: columnar, squamous, and cuboidal.

Columnar Epithelial Tissue

Epithelial cells of this type are elongated, longer than they are wide. Columnar tissue is composed of a single layer of cells whose nuclei are located at about the same level as the nuclei in their neighboring cells (fig. 1-3). These cells can be located in the linings of the uterus, in various organs of the digestive system, and in the passages of the respiratory system. In the digestive system, the chief function of columnar tissue is the secretion of digestive fluids and the absorption of nutrients from digested foods. In certain areas (such as the nostrils, bronchial tubes, and trachea), this tissue has a crown of microscopic hairlike processes known as **cilia**. These cilia provide motion to move secretions

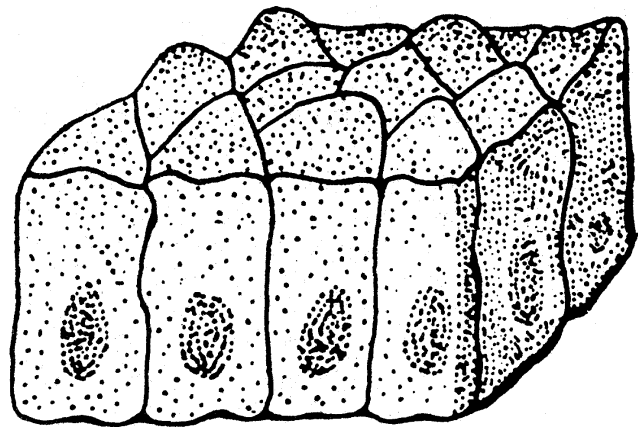


Figure 1-3.—Columnar epithelial tissue.

and other matter along the surfaces from which they extend. They also act as a barrier, preventing foreign matter from entering these cavities.

Squamous Epithelial Tissue

Squamous epithelial tissue is composed of thin platelike or scalelike cells forming a mosaic pattern (fig. 1-4). This tissue is found in the tympanic membrane (eardrum) as a single layer of cells, or in the free skin surface in multiple layers. Squamous tissue is the main protective tissue of the body.

Cuboidal Epithelial Tissue

The cells of cuboidal tissue are cubical in shape (fig. 1-5) and are found in the more highly specialized organs of the body, such as the ovary and the kidney. In the kidneys, cuboidal tissue functions in the secretion and absorption of fluids.




Figure 1-4.—Squamous epithelial tissue.




Figure 1-5.—Cuboidal epithelial tissue.

CONNECTIVE TISSUE

This is the supporting tissue of the various structures of the body. It has many variations and is the most widespread tissue of the body. Connective tissue is highly vascular, surrounds other cells, encases internal organs, sheathes muscles, wraps bones, encloses joints, and provides the supporting framework of the body. Structures of connective tissue differ widely, ranging from delicate tissue-paper membranes to rigid bones. Connective tissue is composed of cells and **extracellular materials** (materials found outside the cells). Extracellular materials include fibers and the **ground substance**. The ground substance contains proteins, water, salts, and other diffusible substances. These extracellular materials give connective tissue varying amounts of elasticity and strength, depending on the type of tissue and location. In the following paragraphs we will discuss the three predominant types of connective tissue: areolar, adipose, and osseous.

Areolar Connective Tissue

Areolar tissue consists of a meshwork of thin fibers that interlace in all directions, giving the tissue both elasticity and tensile strength (fig. 1-6). This type of connective tissue is extensively distributed throughout the body, and its chief function is to bind parts of the body together. Areolar tissue allows a considerable amount of movement to take place because of its elasticity. It is found between muscles and as an outside covering for blood vessels and nerves. The areolar tissue layer connects the blood vessels and nerves to the surrounding structures.

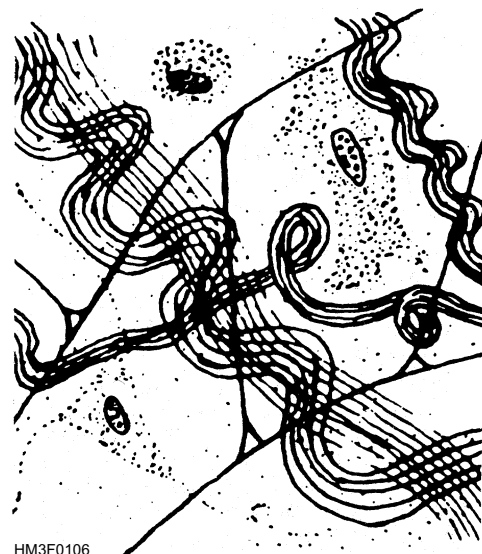

Figure 1-6.—Areolar connective tissue.

Adipose Connective Tissue

Adipose tissue is “fatty tissue.” The adipose cell at first appears star-shaped. When the cell begins to store fat in its cytoplasm, it enlarges, losing its star shape as the nucleus is pushed to one side (fig. 1-7). When this process occurs to many cells, the other cell types are crowded out and adipose tissue is formed. Adipose tissue is found beneath skin, between muscles, and around joints and various organs of the body. Adipose tissue acts as a reservoir for energy-producing foods; helps to reduce body heat loss (because of its poor heat conductivity); and serves as support for various organs and fragile structures, such as the kidneys, blood vessels, and nerves.

Osseous Connective Tissue

This type of tissue, known as “bone tissue,” is a dense fibrous connective tissue that forms tendons, ligaments, cartilage, and bones (fig. 1-8). These tissues form the supporting framework of the body.

MUSCULAR TISSUE

Muscular tissue provides for all body movement. Contracting muscles cause body parts to move. The three types of muscle tissue are skeletal, smooth, and cardiac.

Skeletal Muscle Tissue

Skeletal (voluntary) muscle fiber is striated, or striped, and is under the control of the individual's will (fig. 1-9). For this reason, it is often called “voluntary” muscle tissue. Skeletal muscle tissues are usually attached to bones. When muscle fibers are stimulated by an action of a nerve fiber, the fibers contract and relax. This interaction between muscle and nervous fibers produces movement.

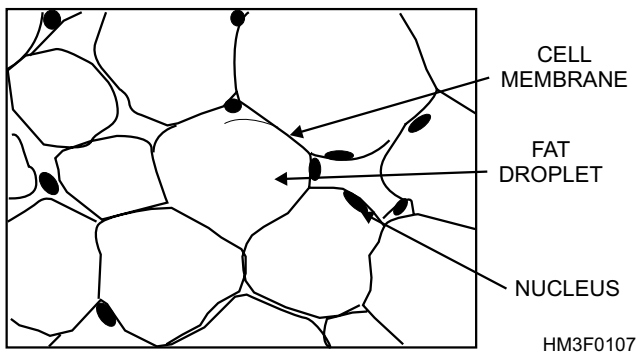


Figure 1-7.—Adipose connective tissue.




Figure 1-8.—Osseous (bone) connective tissue.

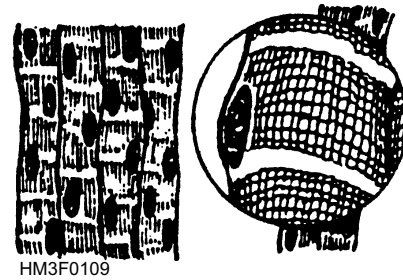


Figure 1-9.—Skeletal muscle tissue.

Smooth Muscle Tissue

These muscle fibers are smooth, or nonstriated, and are not under the control of the individual's will (fig. 1-10). For this reason, this type of muscle tissue is called “involuntary.” Smooth muscle tissue is found in the walls of hollow organs, such as the stomach, intestines, blood vessels, and urinary bladder. Smooth muscle tissues are responsible for the movement of food through the digestive system, constricting blood vessels, and emptying the bladder.




Figure 1-10.—Smooth muscle tissue.

Cardiac Muscle Tissue

The cardiac muscle cells are striated and are joined end to end, resulting in a complex network of interlocking cells (fig. 1-11). Cardiac muscles are involuntary muscles and are located only in the heart. These tissues are responsible for pumping blood through the heart chambers and into certain blood vessels.

NERVE TISSUE

Nerve tissue is the most complex tissue in the body. It is the substance of the brain, spinal cord, and nerves. Nerve tissue requires more oxygen and nutrients than any other body tissue. The basic cell of the nerve tissue is the **neuron** (fig. 1-12). This highly specialized cell receives stimuli from, and conducts impulses to, all parts of the body.

ORGANS

LEARNING OBJECTIVE: *Recall how organs and body systems are composed of two or more kinds of tissue that perform specialized functions within the body.*




Figure 1-11.—Cardiac muscle tissue.

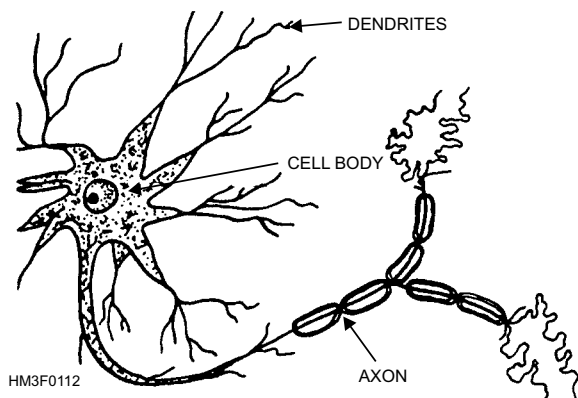


Figure 1-12.—Neuron.

As a group of similar cells forms tissues, two or more kinds of tissues grouped together and performing specialized functions constitute an organ. Organs are grouped together to form systems (such as the urinary system, composed of the kidneys, ureters, bladder, and urethra).

THE SKELETAL SYSTEM

LEARNING OBJECTIVE: *Identify the parts of bone and their functions.*

The skeleton, the bony framework of the body, is composed of 206 bones (fig. 1-13). It supports and gives shape to the body; protects vital organs; and provides sites of attachment for tendons, muscles, and ligaments. The skeletal bones are joined members that make muscle movement possible.

ANATOMY OF BONES

Osteology is the study of the structure of bone. Bone is made up of inorganic mineral salts (calcium and phosphorus being the most prevalent) and an organic substance called **ossein**. If human bones were soaked in dilute acid until all inorganic mineral salts were washed out, all that would remain would be a flexible piece of tissue that could be easily bent and twisted. Inorganic mineral salts give bone its strength and hardness.

Bone consists of a hard outer shell, called **compact bone**, and an inner spongy, porous portion, called **cancellous tissue** (fig. 1-14). In the center of the bone is the **medullary canal**, which contains **marrow**. There are two types of marrow, red and yellow. Yellow marrow is ordinary bone marrow in which fat cells predominate. It is found in the medullary canals and cancellous tissue of long bones. Red marrow is one of the manufacturing centers of red blood cells and is found in the articular ends of long bones and in cancellous tissue.

At the ends of the long bones is a smooth, glossy tissue that forms the joint surfaces. This tissue is called **articular cartilage** because it articulates (or joins) with, fits into, or moves in contact with similar surfaces of other bones. The thin outer membrane surrounding the bone is called the **periosteum**. An important function of the periosteum is to supply nourishment to the bone. Capillaries and blood vessels run through the periosteum and dip into the bone surface, supplying it with blood and nutrients. The

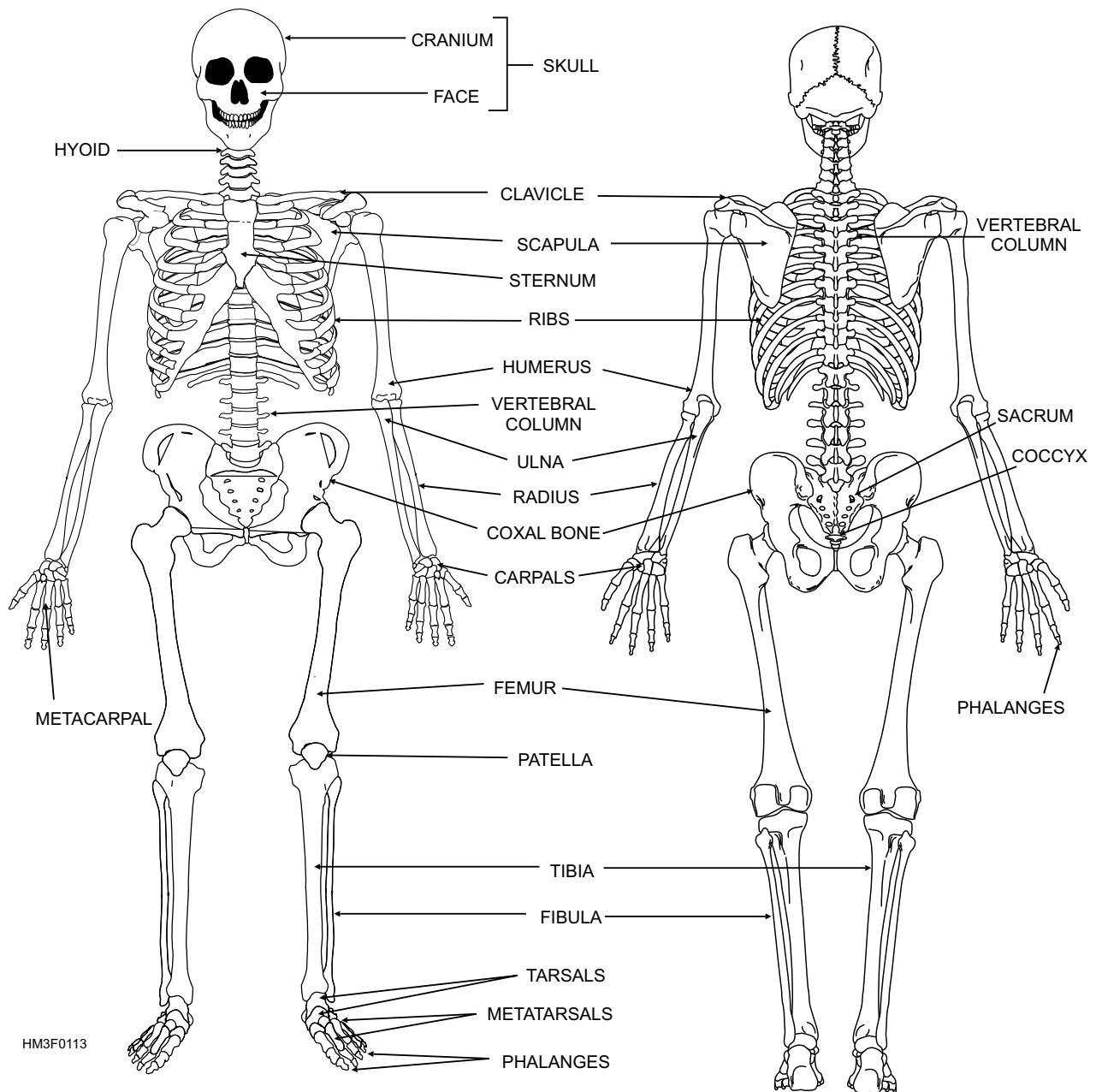


Figure 1-13.—Human skeleton.

periosteum is the pain center of the bone. When a bone fractures, the pain that is felt comes from the periosteum, not the bone proper. Periosteum also forms new bone. The **diaphysis** is the elongated, cylindrical portion (or “shaft”) of the bone that is between the **epiphyses** (*sing.* epiphysis) or ends of the bone.

BONE CLASSIFICATIONS

Bones are classified according to their shape. The four bone classifications and examples of each are as follows:

- **Long bones**—femur and humerus
- **Short bones**—wrist and ankle bones

- **Flat bones**—skull, sternum, and scapula
- **Irregular bones**—vertebrae, mandible, and pelvic bones

DIVISIONS OF SKELETON

The human skeleton is divided into two main divisions, the axial skeleton and the appendicular skeleton.

Axial Skeleton

The axial skeleton consists of the skull, the vertebral column, and the thorax.

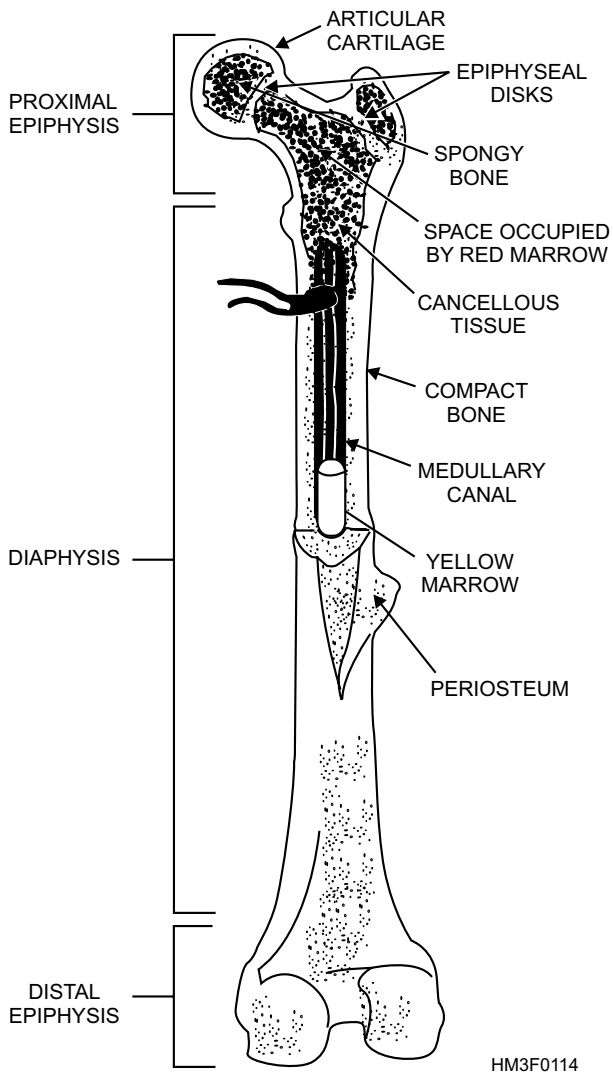


Figure 1-14.—Anatomy of a long bone.

SKULL.—The skull consists of 28 bones (figs. 1-15 and 1-16), 22 of which form the framework of the head and provide protection for the brain, eyes, and ears; six are ear bones. With the exception of the lower jaw bone and the ear bones, all skull bones are joined together and fixed in one position. The seams where they join are known as **sutures**. The bones of the skull are classified as either cranial or facial bones.

Cranial Bones.—The cranium is formed by eight major bones, most of which are in pairs (fig. 1-15). The **frontal bone** forms the forehead and the roof of each orbit (or eye socket) and the nasal cavity. The **parietal bones** form the roof of the skull. The **temporal bones** help form the sides and base of the skull and also house the auditory and hearing organs. The **occipital bone** forms part of the base and back of the skull, and contains a large hole called the foramen magnum. This opening permits passage of the spinal cord from the cranium into the spinal column. The **sphenoid bones** are wedged between several other bones in the anterior portion of the skull. These bones help form the base of the cranium, the sides of the skull, and the floors and sides of the orbits. The **ethmoid bones** are located in front of the sphenoid bone. They form sections of the nasal cavity roof, the cranial floor, and the orbital wall.

Facial Bones.—The facial bones of the skull consists of 14 bones: 13 immovable bones and a movable lower jawbone (fig. 1-16). The facial bones give the face its basic shape and provide attachment sites for various muscles that move the jaw and control facial expressions.

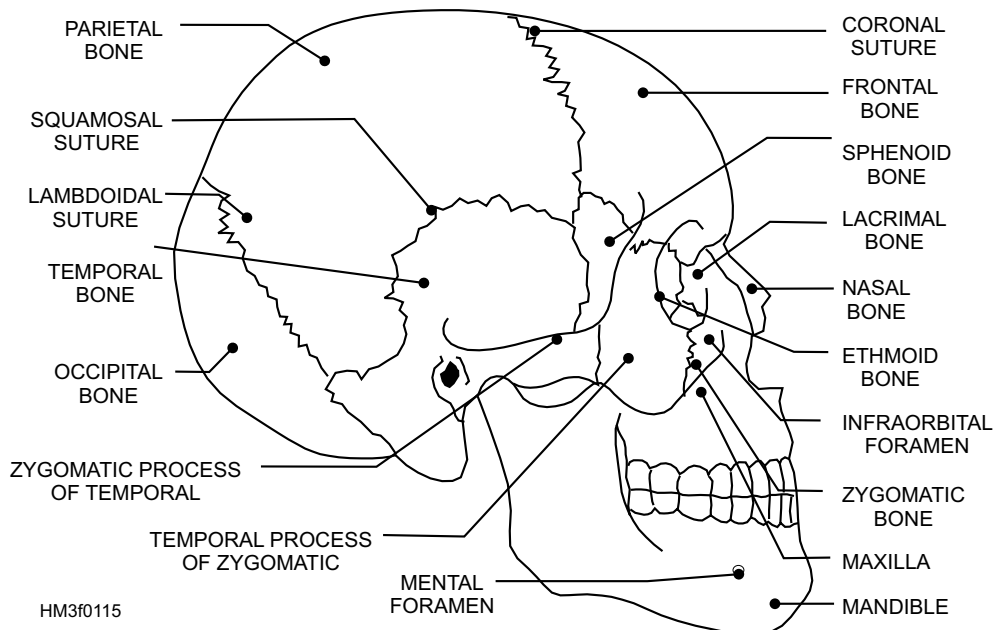


Figure 1-15.—Lateral view of the skull.

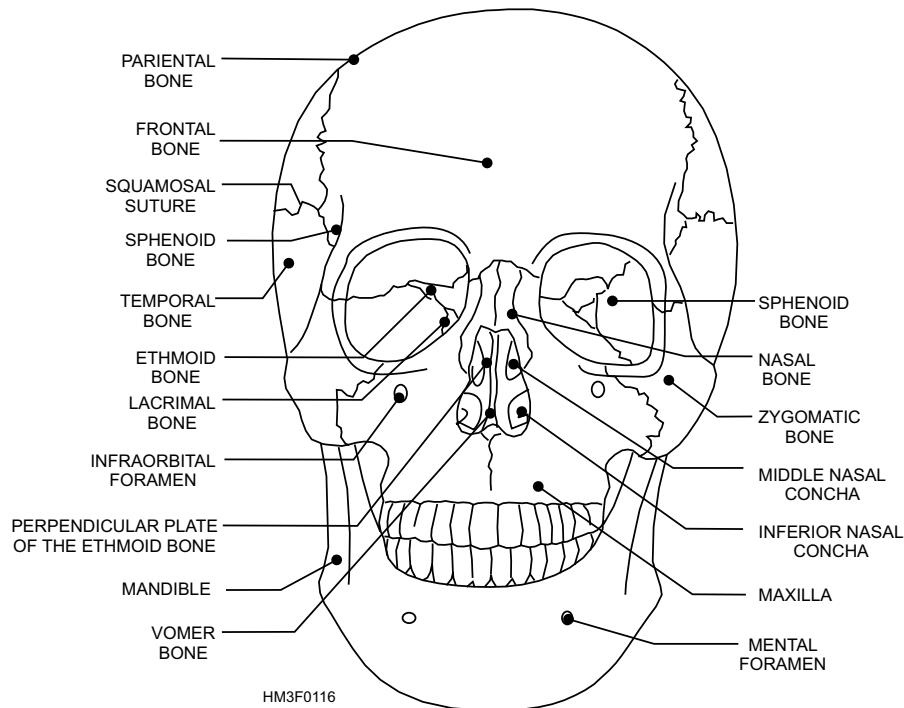


Figure 1-16.—Facial bones.

The **maxillary bones** form the upper jaw, the anterior roof of the mouth, the floors of the orbits, and the sides and floor of the nasal cavity. The small holes on each side of the nasal opening are called the **infraorbital foramina** (*sing.* foramen). The maxillary bones contain large cavities called **maxillary sinuses**.

The palatine bones are L-shaped bones located behind the maxillary bones. They form the posterior section of the hard palate and the floor of the nasal cavity.

The **zygomatic bones** are responsible for the prominence of the cheeks. The zygomatic bones serve as part of the posterior section of the hard palate and the floor of the nasal cavity.

The **lacrimal bones** provide a pathway for a tube that carries tears from the eye to the nasal cavity. The lacrimal bone is a thin, scalelike structure located in the medial wall of each orbit.

The **nasal bones** have cartilaginous tissues attached to them. These tissues contribute significantly to the shape of the nose. The nasal bones are long, thin, and nearly rectangular in shape. They lie side by side and are fused together to form the bridge of the nose.

The **vomer bone** is connected to the ethmoid bone, and together they form the nasal septum (the wall separating the two nasal cavities).

The **middle and inferior nasal conchae** are fragile, scroll-shaped bones that are attached to the lateral wall of the nasal cavity. The inferior nasal concha provides support for mucous membranes within the nasal cavity.

The lower jawbone is called the **mandible**. The mandible is horseshoe-shaped with flat, bony projections on each end. The two small holes on the jawbone are called the **mental foramina**. The mandible's main function is mastication (chewing food).

VERTEBRAL (SPINAL) COLUMN.—The vertebral column consists of 24 movable or true vertebrae; the sacrum; and the coccyx, or tail bone (fig. 1-17). The vertebrae protect the spinal cord and the nerves that branch out from the spinal cord. Each vertebra has an anterior portion, called the body, which is the large solid segment of the bone (fig. 1-18). This vertebral body supports not only the spinal cord but other structures of the body as well. At the bottom of the spinal column is the **sacrum** and the **coccyx**. Many of the main muscles are attached to the vertebrae.

The **vertebral foramen** is a hole directly behind the body of the vertebrae that forms the passage for the spinal cord. The vertebral projections are for the attachments of muscles and ligaments and for facilitating movement of one vertebra over another. The spinal column is divided into five regions in the following order: cervical (neck), thoracic (chest),

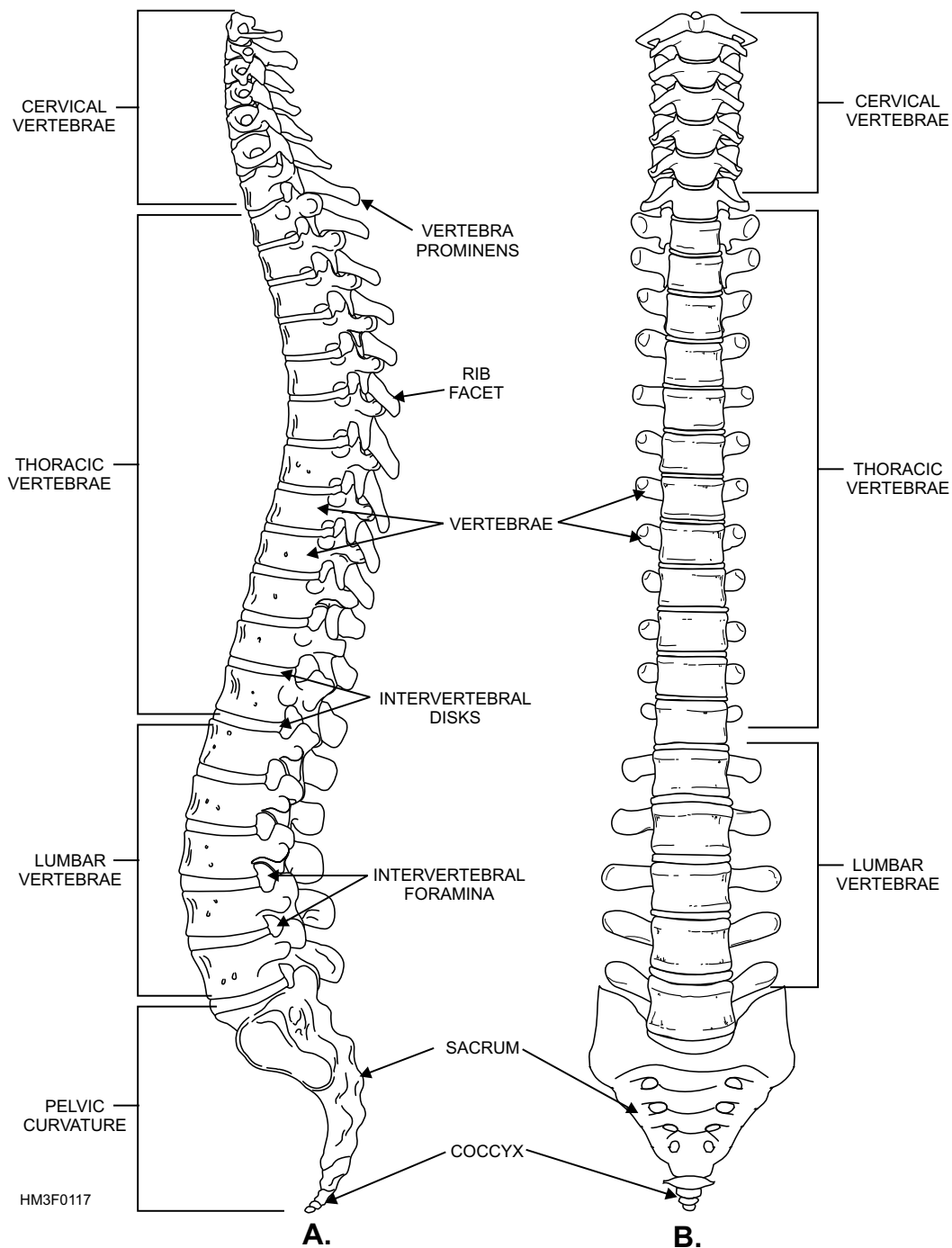


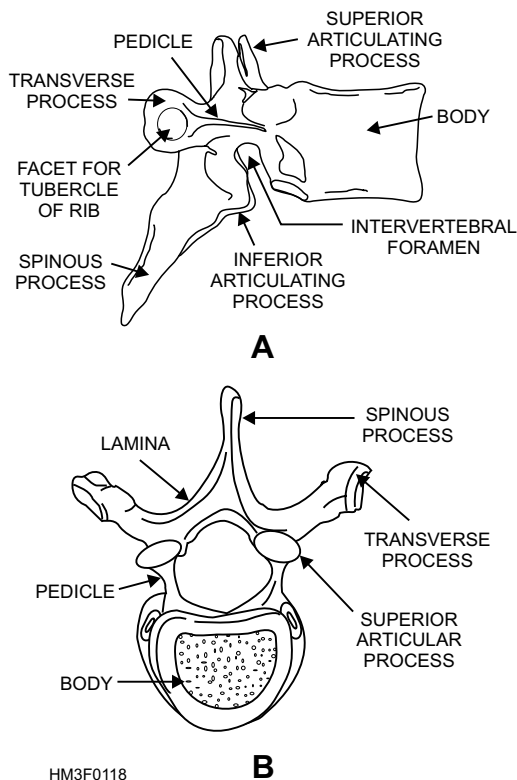
Figure 1-17.—Vertebral column: A. Left lateral view of vertebral column; B. Posterior view of vertebral column.

lumbar (lower back), and sacral and coccygeal (pelvis).

Cervical.—There are seven cervical vertebrae in the neck. The first is called the **atlas** and resembles a bony ring. It supports the head. The second is the highly specialized **axis**. It has a bony prominence that fits into the ring of the atlas, thus permitting the head to rotate from side to side. The atlas and the axis are the only named vertebrae; all others are numbered. See figure 1-19. Each cervical vertebra has a transverse (or

intervertebral) foramen (fig. 1-19) to allow passage of nerves, the vertebral artery, and a vein. The seventh cervical vertebra has a prominent projection that can easily be felt at the nape of the neck. This landmark makes it possible for physicians to count and identify the vertebrae above and below it.

Thoracic.—There are 12 vertebrae in the thoracic region. The thoracic vertebrae articulate with the posterior portion of the 12 ribs to form the posterior wall of the thoracic, or chest, cage.

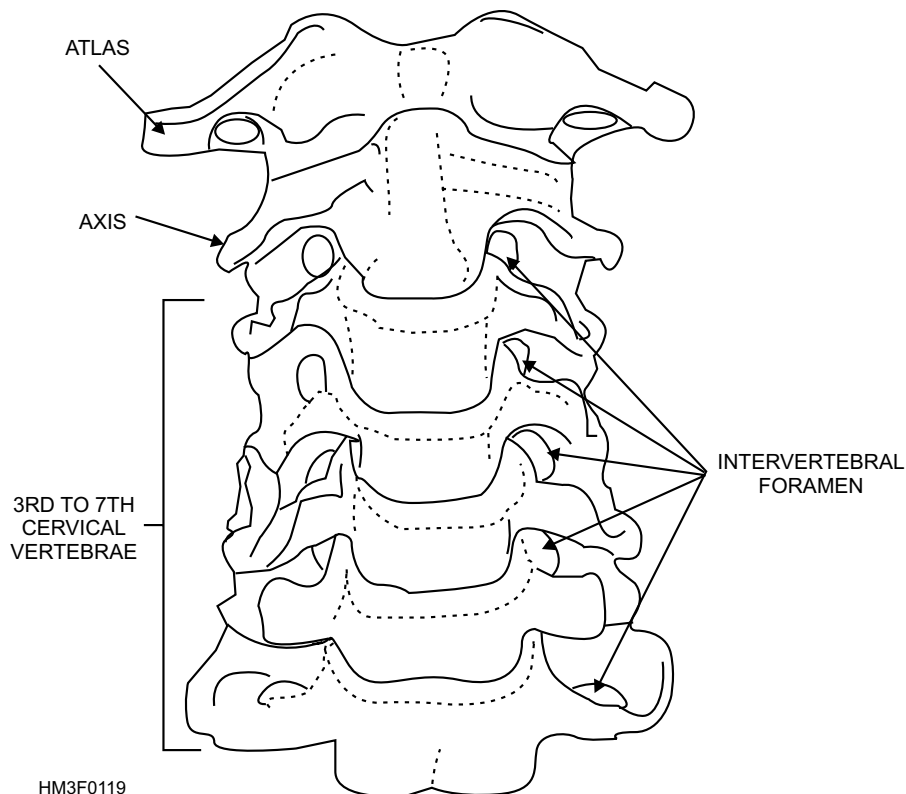


HM3F0118
Figure 1-18.—Typical vertebra: A. Lateral view of a typical vertebra; B. Superior view of a typical thoracic vertebra.

Lumbar.—There are five lumbar vertebrae. Located in the small of the back, these vertebrae are the larger and stronger segments of the vertebral column.

Sacrum.—The sacrum is the triangular bone immediately below the lumbar vertebrae. It is composed of five separate vertebrae that gradually fuse together between 18 and 30 years of age. The sacrum is connected on each side with the hip bone and with the **coccyx** to form the posterior wall of the **pelvis**.

THORAX.—This cone-shaped bony cage is about as wide as it is deep (fig. 1-20). The thorax is formed by 12 ribs on each side and articulates posteriorly with the thoracic vertebrae. The first set of ribs are attached to the **manubrium**, a flat irregular bone atop the sternum. The first seven pairs of ribs are called **true ribs**. The remaining five pairs are called **false ribs**. They are called false ribs because their cartilages do not reach the sternum directly. The eighth, ninth, and tenth ribs are united by their cartilages and joined to the rib above. The last two rib pairs, also known as **floating ribs**, have no cartilaginous attachments to the **sternum**. The sternum is an elongated flat bone, forming the middle portion of the upper half of the chest wall in front. The **xiphoid process**, located at the inferior aspect of the sternum, serves as a landmark in the administration of cardiopulmonary resuscitation.



HM3F0119
Figure 1-19.—Cervical vertebrae.

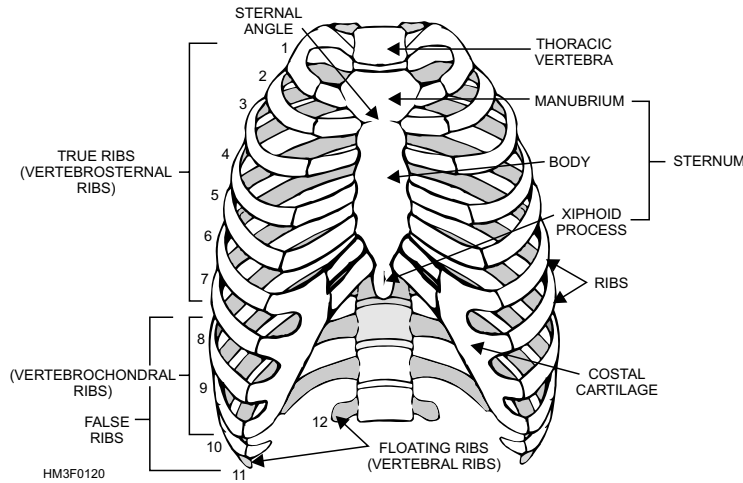


Figure 1-20.—Anterior view of thorax,

Appendicular Skeleton

The appendicular skeleton consists of the bones of the upper and lower extremities.

UPPER EXTREMITY.—The upper extremity consists of the bones of the shoulder, the arm, the forearm, the wrist, and the hand (figs. 1-21 and 1-22). The bones that form the framework for the upper extremities are listed in table 1-1.

Table 1-1.—Bones of the Upper Extremities

BONE	COMMON NAME	TOTAL NUMBER IN BODY
clavicle	collar bone	2
scapula	shoulder blade	2
humerus	arm bone	2
radius and ulna	forearm bones	4
carpals	wrist bones	16
metacarpals	bones of the palm	10
phalanges	finger bones	28

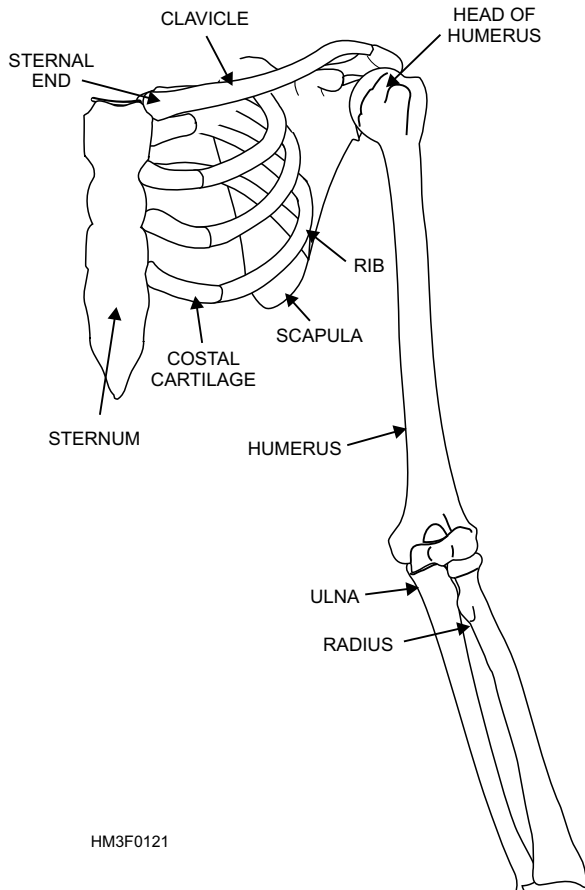
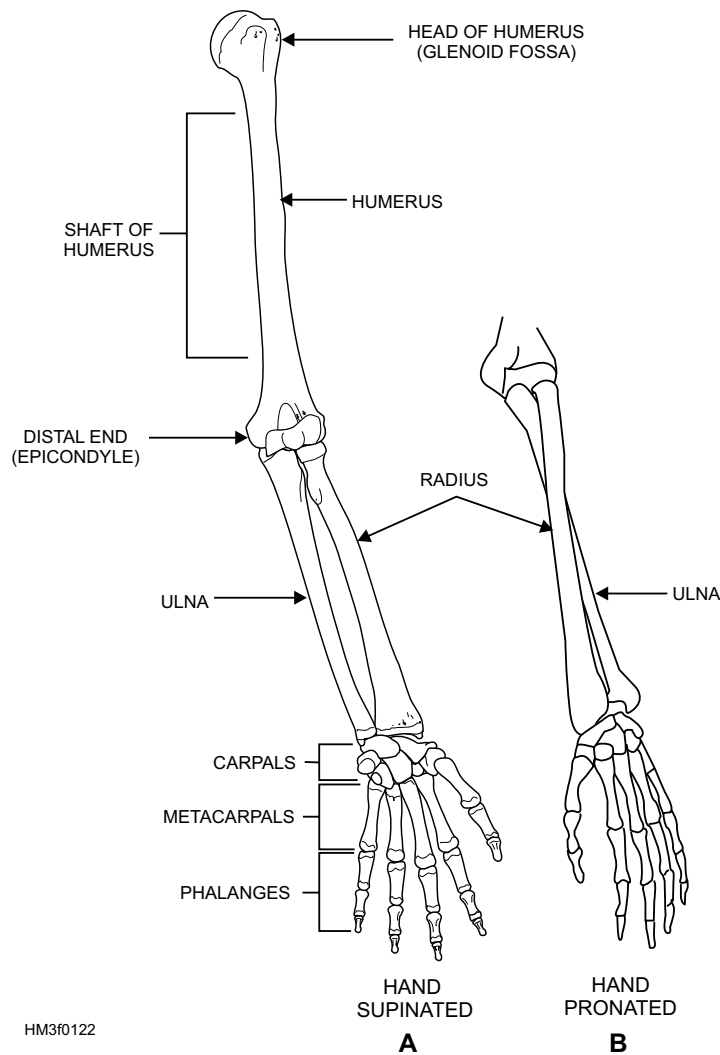


Figure 1-21.—Pectoral girdle.

Clavicle.—The clavicle (commonly called the collar bone) lies nearly horizontally above the first rib and is shaped like a flat letter S. The clavicle is a thin brace bone that fractures easily. Its inner end is round and attached to the sternum; its outer end is flattened and fixed to the scapula. The clavicle forms the anterior portion of the pectoral girdle (fig. 1-21). The pectoral girdle is composed of the two clavicles and two scapulae (shoulder blades). It functions as a support for the arms and serves as an attachment for several muscles.

Scapula.—The scapula is a triangular bone that lies in the upper part of the back on both sides, between the second and seventh ribs, forming the posterior portion of the pectoral girdle. Its lateral corner forms part of the shoulder joint, articulating with the humerus.

Humerus.—The humerus is the longest bone of the upper extremity and is often called the arm bone (fig. 1-22). It articulates with the pectoral girdle to form the shoulder joint, and with the bones of the



HM3f0122

Figure 1-22.—Left arm: A. Frontal view of left arm with hand supinated; B. Frontal view of left arm with hand pronated.

forearm to form the elbow. Its anatomical portions include a head (a rounded portion that fits into a recess of the scapula) called the **glenoid fossa**; the **shaft**, which is the main part of the humerus; and the **distal end**, which includes the prominence (called an **epicondyle**) and the surfaces that articulate with the bones of the forearm.

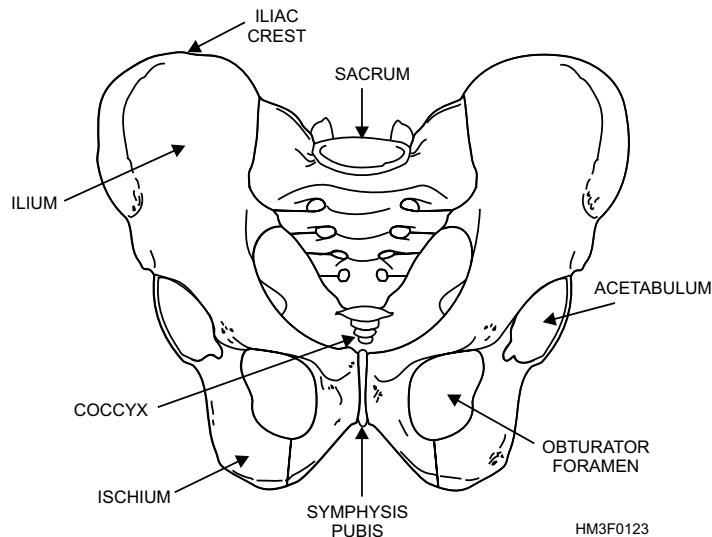
Radius and Ulna.—When the arm is in the anatomical position with the palm turned forward, the **radius** is on the lateral (thumb) side and the **ulna** is on the medial (little finger) side of the forearm (fig. 1-22). When the hand is pronated (with the palm turned downward), the bones rotate on each other and cross in the middle. This pronation makes it possible to turn the wrist and hand (as when opening doors). The ulna and the radius articulate at their proximal ends with the humerus, at their distal ends with some of the carpal bones, and with each other at both ends.

Carpal.—There are eight carpal bones, arranged in two rows, forming the wrist.

Metacarpal.—The metacarpal bones are numbered one to five, corresponding with the five fingers, or digits, with which they articulate. The fingers are named as follows: 1st—thumb; 2nd—index; 3rd—middle; 4th—ring; and 5th—little.

Phalanges.—The small bones of the fingers are called phalanges, and each one of these bones is called a **phalanx**. Each finger has three phalanges, except the thumb (which has two). The phalanges are named for their anatomical position: The proximal phalanx is the bone closest to the hand; the distal phalanx is the bone at the end of the finger; and the middle phalanx is the bone located between the proximal and distal phalanges.

LOWER EXTREMITY.—The lower extremity includes the bones of the hip, thigh, leg, ankle, and foot. The bones that form the framework of the lower extremities are listed in table 1-2.



HM3F0123

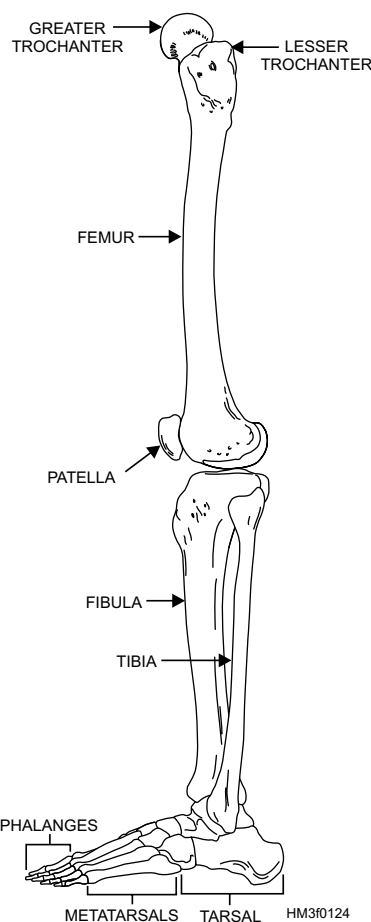
Figure 1-23.—Pelvic girdle.

Table 1-2.—Bones of the Lower Extremities

BONE	COMMON NAME	TOTAL NUMBER IN BODY
innominate	hip bone	2
femur	thigh bone	2
patella	knee cap	2
tibia	leg bone	2
fibula	leg bone	2
tarsals	ankle bones	14
metatarsals	foot bones	10
phalanges	toe bones	28

Innominate.—The innominate bone, commonly known as the hip, is a large, irregularly shaped bone composed of three parts: the ilium, ischium, and pubis (fig. 1-23). In children these three parts are separate bones, but in adults they are firmly united to form a cuplike structure, called the **acetabulum**, into which the head of the femur fits. The **ilium** forms the outer prominence of the hip bone (the crest of the ilium, referred to as the **iliac crest**, provides an anatomical landmark above the ilium); the **ischium** forms the hard lower part; and the **pubis** forms the front part of the pelvis.

Symphysis Pubis.—The area where the two pubic bones meet is called the symphysis pubis and is often used in anatomical measurements. The largest foramen, or opening, is located in the hip bone, between the ischium and the pubis, and is called the **obturator foramen** (fig. 1-23). The crest of the ilium



HM3F0124

Figure 1-24.—Anterior view of the right leg.

is used in making anatomical and surgical measurements (e.g., location of the appendix, which is approximately halfway between the crest of the ilium and the umbilicus).

Femur.—The femur, or thigh bone, is the longest bone in the body (fig. 1-24). The proximal end is rounded and has a head supported by a constricted neck

that fits into the acetabulum. Two processes called the **greater** and **lesser trochanters** are at the proximal end for the attachment of muscles. The neck of the femur, located between the head and the trochanters, is the site on the femur most frequently fractured. At the distal end are two bony prominences, called the **lateral** and **medial condyles**, which articulate with the tibia and the patella.

Patella.—The patella is a small oval-shaped bone overlying the knee joint. It is enclosed within the tendon of the quadriceps muscle of the thigh. Bones like the patella that develop within a tendon are known as **sesamoid** bones.

Tibia.—The tibia, or shin bone, is the larger of the two leg bones and lies at the medial side. The proximal end articulates with the femur and the fibula. Its distal end articulates with the talus (one of the foot bones) and the fibula (fig. 1-25). A prominence easily felt on the inner aspect of the ankle is called the **medial malleolus**.

Fibula.—The fibula, the smaller of the two leg bones, is located on the lateral side of the leg, parallel to the tibia. The prominence at the distal end forms the outer ankle and is known as the **lateral malleolus**.

Tarsus.—The tarsus, or ankle, is formed by seven tarsal bones: **medial cuneiform, intermediate cuneiform, lateral cuneiform, cuboid, navicular, talus, and calcaneus**. The strongest of these is the heel bone, or **calcaneus**.

Metatarsus.—The sole and instep of the foot is called the metatarsus and is made up of five

metatarsal bones (fig. 1-25). They are similar in arrangement to the metacarpals of the hand.

Phalanges.—The phalanges are the bones of the toes and are similar in number, structure, and arrangement to the bones of the fingers.

JOINTS

LEARNING OBJECTIVE: *Recognize joint classifications and identify joint movements for the key joints in the body.*

Wherever two or more bones meet, a joint is formed. A joint binds various parts of the skeletal system together and enables body parts to move in response to skeletal muscle contractions.

JOINT CLASSIFICATIONS

Joints are classified according to the amount of movement they permit (fig. 1-26). Joint classifications are as follows:

- **Immovable.** Bones of the skull are an example of an immovable joint. Immovable joints are characterized by the bones being in close contact with each other and little or no movement occurring between the bones.
- **Slightly movable.** In slightly movable joints, the bones are held together by broad flattened disks of cartilage and ligaments (e.g., vertebrae and symphysis pubis).

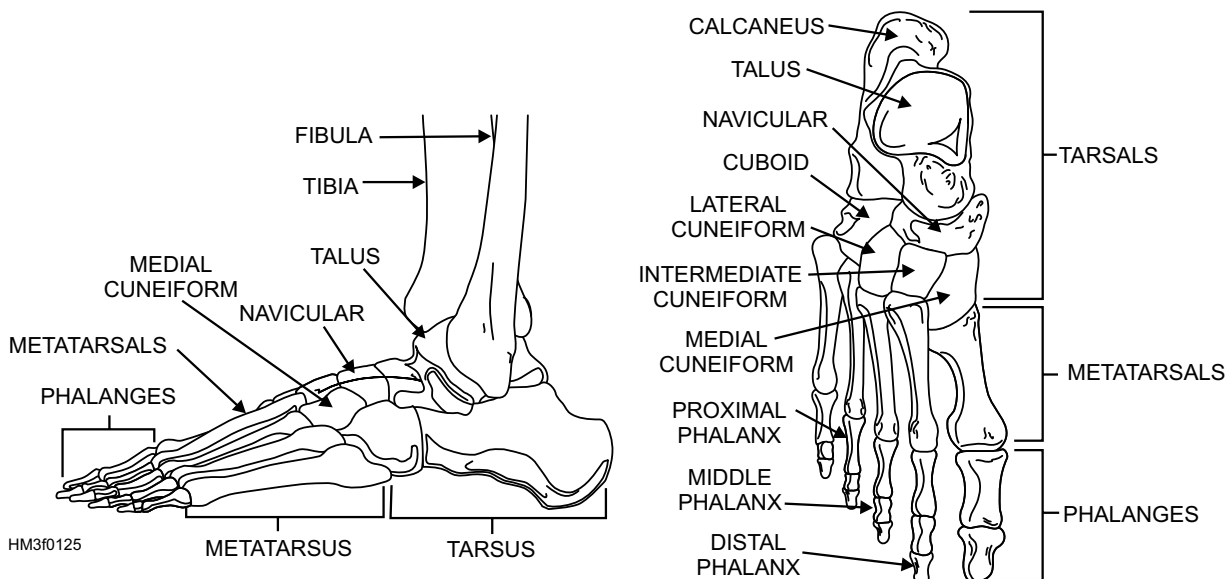


Figure 1-25.—The foot: A. Lateral view of foot; B. Right foot viewed from above.

- **Freely movable.** Most joints in the body are freely movable joints. The joint consists of the **joint capsule, articular cartilage, synovial membrane, and synovial (joint) cavity** (fig. 1-26). There are six classifications of freely movable joints: **ball-in-socket, condyloid, gliding, hinge, pivot, and saddle joints** (fig. 1-27). These joints have much more complex structures than the immovable and slightly movable joints. The ends of the bones in this type of joint are covered with a smooth layer of cartilage. The whole joint is enclosed in a watertight sac or membrane containing a small amount of lubricating fluid. This lubrication enables the joint to work with little friction. **Ligaments** (cords or sheets of connective tissue) reach across the joints from one bone to another and keep the bone stable. When ligaments are torn, we call the injury a sprain; when bones are out of place, we refer to this as a dislocation; and when bones are chipped or broken, the injury is called a fracture.

TYPES OF JOINT MOVEMENTS

Joint movements are generally divided into four types: gliding, angular, rotation, and circumduction.

Gliding

Gliding is the simplest type of motion. It is one surface moving over another without any rotary or angular motion. This motion exists between two adjacent surfaces.

Angular

Angular motion decreases or increases the angle between two adjoining bones. The more common types of angular motion are as follows:

- **Flexion**—bending the arm or leg.
- **Extension**—straightening or unbending, as in straightening the forearm, leg, or fingers.
- **Abduction**—moving an extremity away from the body.
- **Adduction**—bringing an extremity toward the body.

Rotation

Rotation is a movement in which the bone moves around a central point without being displaced, such as turning the head from side to side.

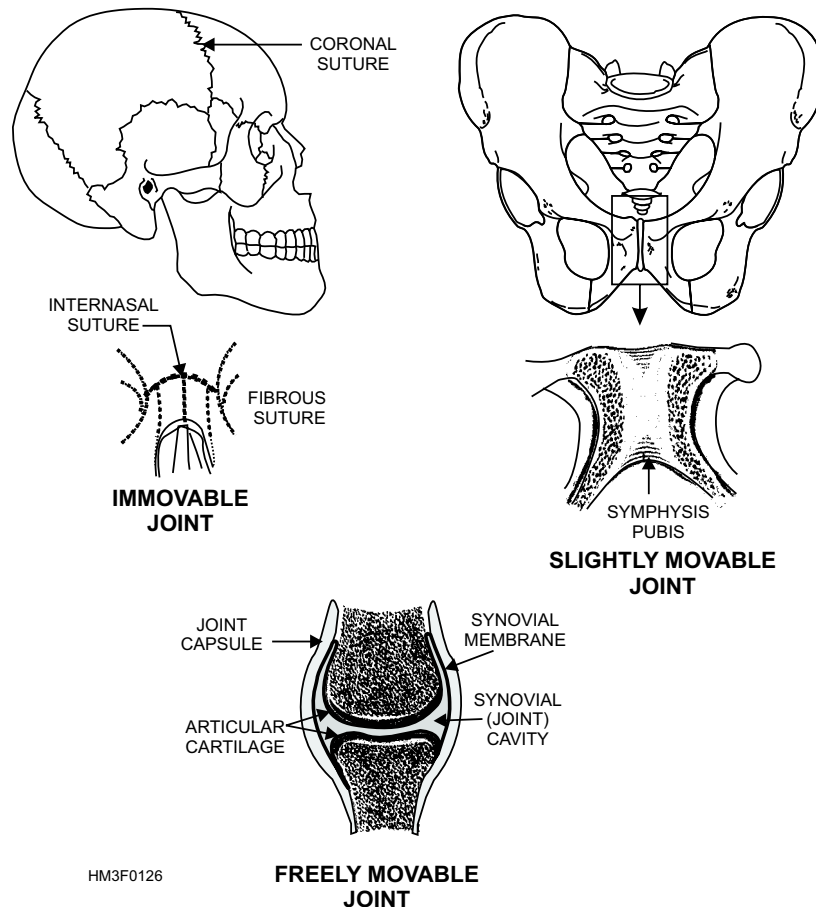


Figure 1-26.—Example of immovable, slightly movable, and freely movable joints.

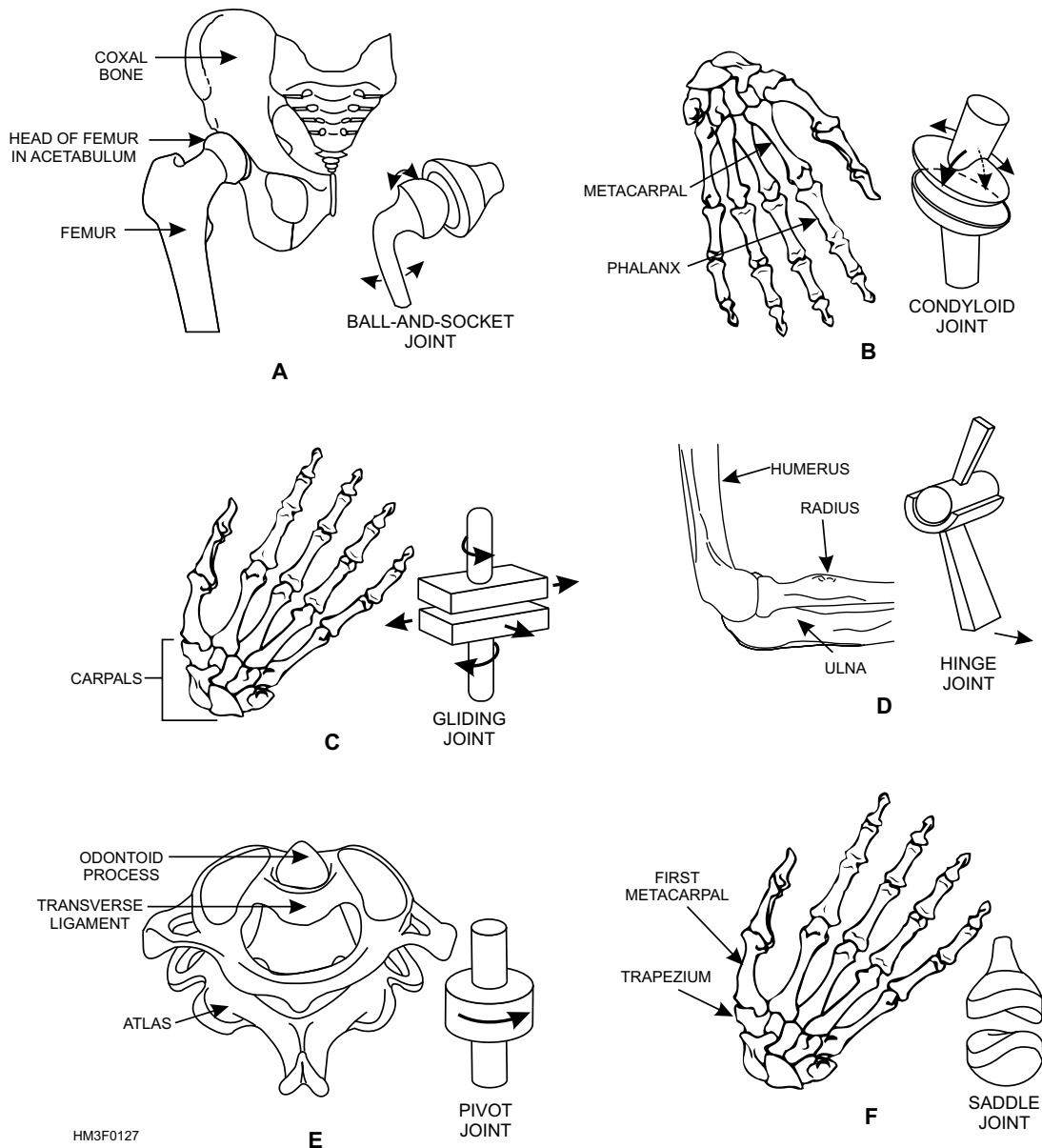


Figure 1-27.—Types of joints: A. Ball-in-socket joint; B. Condylloid joint; C. Gliding joint; D. Hinge joint; E. Pivot joint; F. Saddle joint.

Circumduction

Circumduction is the movement of the hips and shoulders.

Other Types of Movement

Other types of movement generally used to indicate specific anatomical positions include the following:

- **Supination**—turning upward, as in placing the palm of the hand up.
- **Pronation**—turning downward, as in placing the palm of the hand down.

- **Eversion**—turning outward, as in turning the sole of the foot to the outside.
- **Inversion**—turning inward, as in turning the sole of the foot inward.

MUSCLES

LEARNING OBJECTIVE: *Identify primary muscle functions, muscle characteristics, types of muscle tissue, and important functional muscles.*

Muscles are responsible for many different types of body movements. The action of the muscle is

determined mainly by the kind of joint it is associated with and the way the muscle is attached to the joint. At one end of some muscles are long white **tendons** that attach the muscles to bone. The point of fixed attachment of a muscle to bone is called the **origin**. The more flexible attachments, especially attachments to a movable bone, are termed **insertions**.

Muscles seldom act alone; they usually work in groups held together by sheets of a white fibrous tissue called **fascia**. Muscles make up about one-half of the total body weight. Their main functions are threefold:

- **Providing movement**—including internal functions such as peristalsis (rhythmic waves of muscular contraction within the intestines).
- **Maintaining body posture**—through muscle tone, as in the muscles of the head, neck and shoulders, which keep the head up.
- **Providing heat**—through chemical changes that take place during muscle activity, such as exercise that warms the body.

In addition, muscles are involved in such essential bodily functions as respiration, blood circulation, digestion, and other functions such as speaking and seeing.

MUSCLE CONTRACTION

Muscle tissue has a highly developed ability to contract. **Contractibility** enables a muscle to become shorter or thicker, and this ability, along with interaction with other muscles, produces movement of internal and external body parts. Muscle contraction in a tissue or organ produces motion and provides power and speed for body activity. A contracting muscle is referred to as a **prime mover**. A muscle that is relaxing while a prime mover is contracting is called the **antagonist**.

STIMULUS FOR CONTRACTION

All muscles respond to stimulus. This property is called **excitability** or **irritability**. The mechanical muscular action of shortening or thickening (also called contraction) is activated by a stimulus sent through a motor nerve. All muscles are linked to nerve fibers that carry messages from the central nervous system.

CONTRACTION AND RECOVERY

The chemical action of muscle fibers consists of two stages, **contraction** and **recovery**. In the contraction stage, two protein substances (actin and myosin) react to provide energy through the breakdown of glycogen into lactic acid. In the recovery stage, oxygen reacts with lactic acid to release carbon dioxide and water.

MUSCLE FATIGUE

When a muscle contracts, it produces chemical waste products (carbon dioxide, lactic acid, and acid phosphate) which make the muscle more irritable. If contraction is continued, the muscle will cramp and refuse to move. This condition is known as **fatigue**. If it is carried too far, the muscle cells will not recover and permanent damage will result. Muscles, therefore, need rest to allow the blood to carry away the waste materials and bring in fresh glucose, oxygen, and protein to restore the muscle protoplasm and the energy that was used.

TONICITY

Tonicity, or muscular tone, is a continual state of partial contraction that gives muscles a certain firmness. **Isometric** muscle contraction occurs when the muscle is stimulated and shortens, but no movement occurs, as when a person tenses his or her muscles against an immovable object. **Isotonic** muscle contraction occurs when the muscle is stimulated. The muscle shortens and movement occurs. An example would be lifting an object.

EXTENSIBILITY AND ELASTICITY

Muscles are also capable of stretching when force is applied (**extensibility**) and regaining their original form when that force is removed (**elasticity**).

MAINTENANCE OF MUSCLE TISSUE

During exercise, massage, or ordinary activities, the blood supply of muscles is increased. This additional blood brings in fresh nutritional material, carries away waste products more rapidly, and enables the muscles to build up and restore their efficiency and tone.

The importance of exercise for normal muscle activity is clear, but excessive muscle strain is damaging. For example, if a gasoline motor stands

idle, it eventually becomes rusty and useless. Similarly, a muscle cell that does not work atrophies, becoming weak and decreasing in size. On the other hand, a motor that is never allowed to stop and is forced to run too fast or to do too much heavy work soon wears out so that it cannot be repaired. In the same way, a muscle cell that is forced to work too hard without proper rest will be damaged beyond repair.

When a muscle dies, it becomes solid and rigid and no longer reacts. This stiffening, which occurs from 10 minutes to several hours after death, is called **rigor mortis**.

MUSCLE TISSUES

There are three types of muscle tissue: skeletal, smooth, and cardiac. Each is designed to perform a specific function.

Skeletal

Skeletal, or striated, muscle tissues are attached to the bones and give shape to the body. They are responsible for allowing body movement. This type of muscle is sometimes referred to as **striated** because of the striped appearance of the muscle fibers under a microscope (fig. 1-9). They are also called **voluntary** muscles because they are under the control of our conscious will. These muscles can develop great power.

Smooth

Smooth, or nonstriated, muscle tissues are found in the walls of the stomach, intestines, urinary bladder, and blood vessels, as well as in the duct glands and in the skin. Under a microscope, the smooth muscle fiber lacks the striped appearance of other muscle tissue (fig. 1-10). This tissue is also called **involuntary** muscle because it is not under conscious control.

Cardiac

The cardiac muscle tissue forms the bulk of the walls and septa (or partitions) of the heart, as well as the origins of the large blood vessels. The fibers of the cardiac muscle differ from those of the skeletal and smooth muscles in that they are shorter and branch into a complicated network (fig. 1-11). The cardiac muscle has the most abundant blood supply of any muscle in the body, receiving twice the blood flow of the highly vascular skeletal muscles and far more than the smooth muscles. Cardiac muscles contract to pump blood out

of the heart and through the cardiovascular system. Interference with the blood supply to the heart can result in a heart attack.

MAJOR SKELETAL MUSCLES

In the following section, the location, actions, origins, and insertions of some of the major skeletal muscles are covered. In figures 1-28 and 1-29 the superficial skeletal muscles are illustrated. Also note, the names of some of the muscles give you clues to their location, shape, and number of attachments.

Temporalis

The temporalis muscle is a fan-shaped muscle located on the side of the skull, above and in front of the ear. This muscle's fibers assist in raising the jaw and pass downward beneath the zygomatic arch to the mandible (fig. 1-29). The temporalis muscle's origin is the temporal bone. It is inserted in the coronoid process (a prominence of bone) of the mandible.

Masseter

The masseter muscle raises the mandible, or lower jaw, to close the mouth (fig. 1-28). It is the chewing muscle in the mastication of food. It originates in the zygomatic process and adjacent parts of the maxilla and is inserted in the mandible.

Sternocleidomastoid

The sternocleidomastoid muscles are located on both sides of the neck. Acting individually, these muscles rotate the head left or right (figs. 1-28 and 1-29). Acting together, they bend the head forward toward the chest. The sternocleidomastoid muscle originates in the sternum and clavicle and is inserted in the mastoid process of the temporal bone. When this muscle becomes damaged, the result is a common condition known as a "stiff neck."

Trapezius

The trapezius muscles are a broad, trapezium-shaped pair of muscles on the upper back, which raise or lower the shoulders (figs. 1-28 and 1-29). They cover approximately one-third of the back. They originate in a large area which includes the 12 thoracic vertebrae, the seventh cervical vertebra, and the occipital bone. They have their insertion in the clavicle and scapula.

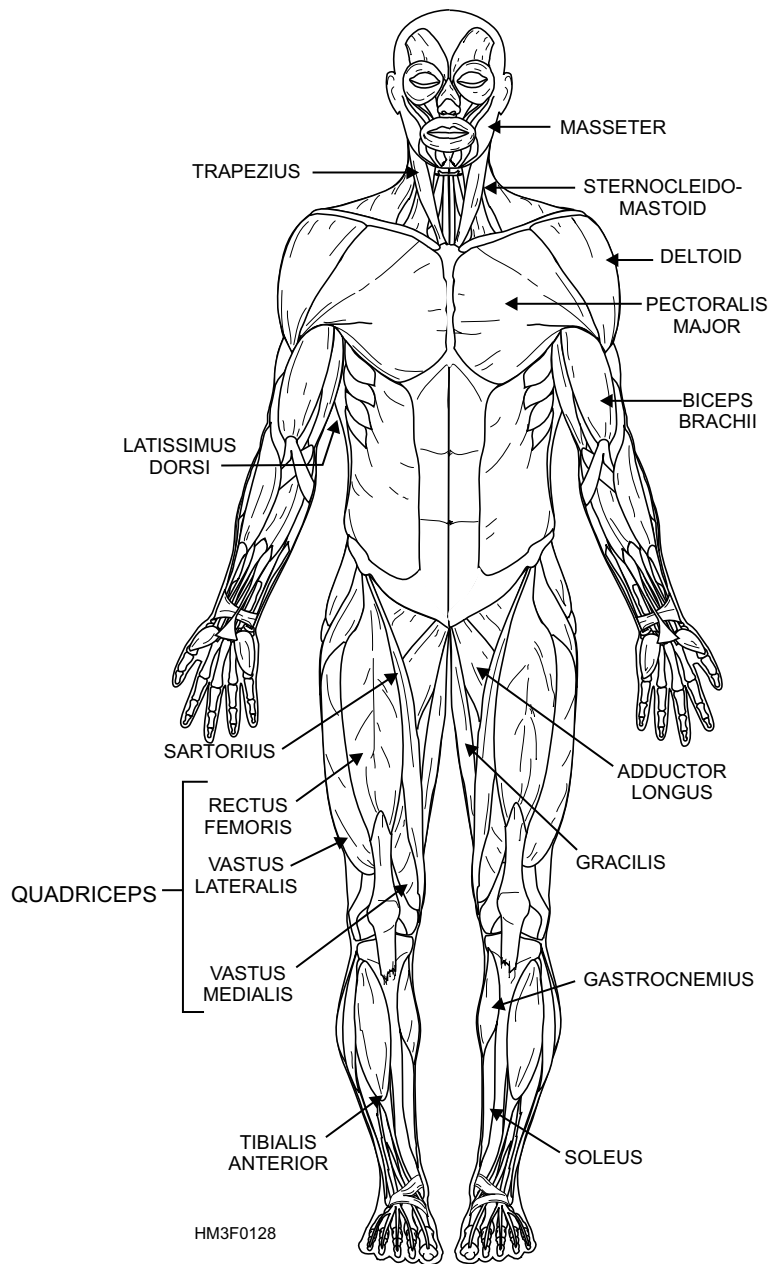


Figure 1-28.—Anterior view of superficial skeletal muscles.

Pectoralis Major

The pectoralis major is the large triangular muscle that forms the prominent chest muscle (fig. 1-28). It rotates the arm inward, pulls a raised arm down toward the chest, and draws the arm across the chest. It originates in the clavicle, sternum, and cartilages of the true ribs, and the external oblique muscle. Its insertion is in the greater tubercle of the humerus.

Deltoid

The deltoid muscle raises the arm and has its origin in the clavicle and the spine of the scapula (figs. 1-28

and 1-29). Its insertion is on the lateral side of the humerus. It fits like a cap over the shoulder and is a frequent site of intramuscular injections.

Biceps Brachii

The biceps brachii is the prominent muscle on the anterior surface of the upper arm (fig. 1-28). Its origin is in the outer edge of the glenoid cavity, and its insertion is in the tuberosity of the radius. This muscle rotates the forearm outward (supination) and, with the aid of the brachial muscle, flexes the forearm at the elbow.

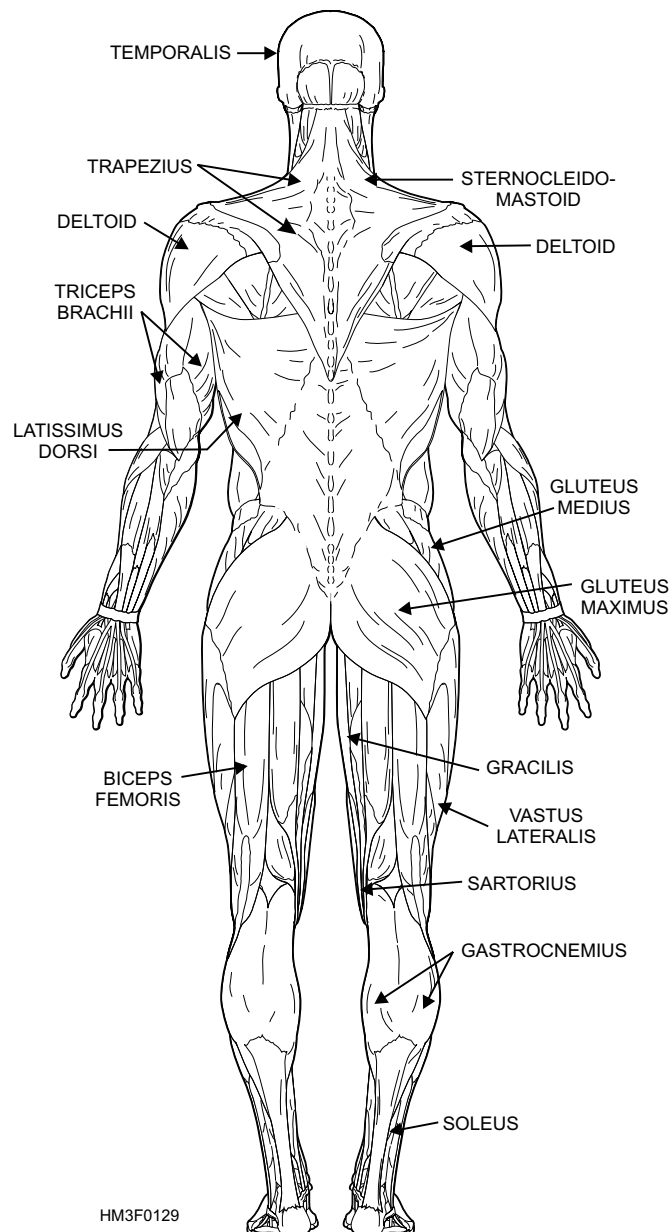


Figure 1-29.—Posterior view of superficial skeletal muscles.

Triceps Brachii

The triceps brachii is the primary extensor of the forearm (the antagonist of the biceps brachii) (fig. 1-29). It originates at two points on the humerus and one on the scapula. These three heads join to form the large muscle on the posterior surface of the upper arm. The point of insertion is the olecranon process of the ulna.

Latissimus Dorsi

The latissimus dorsi is a broad, flat muscle that covers approximately one-third of the back on each side (figs. 1-28 and 1-29). It rotates the arm inward and draws the arm down and back. It originates from the upper thoracic vertebrae to the sacrum and the

posterior portion of the crest of the ilium. Its fibers converge to form a flat tendon that has its insertion in the humerus.

Gluteus

The gluteus (**maximus**, **minimus** (not shown), and **medius**) are the large muscles of the buttocks, which extend and laterally rotate the thigh, as well as abduct and medially rotate it (fig. 1-29). They arise from the ilium, the posterior surface of the lower sacrum, and the side of the coccyx. Their points of insertion include the greater trochanter and the gluteal tuberosity of the femur. The gluteus maximus is the site of choice for intramuscular injections.

Quadriceps

The quadriceps is a group of four muscles that make up the anterior portion of the thigh. The four muscles of this group are the **rectus femoris** that originates at the ilium; and the **vastus lateralis**, **v. medialis**, **v. intermedius** (not shown), that originate along the femur (fig. 1-28). All four are inserted into the tuberosity of the tibia through a tendon passing over the knee joint. The quadriceps serves as a strong extensor of the leg at the knee and flexes the thigh. Additionally located in the quadriceps area is the **adductor longus** that adducts, rotates, and flexes the thigh.

Biceps Femoris

The biceps femoris (often called the hamstring muscle) originates at the tuberosity of the ischium (the lowest portion of the coxal bone, part of the pelvic girdle) and the middle third of the femur (fig. 1-29). It is inserted on the head of the fibula and the lateral condyle of the tibia. It acts, along with other related muscles, to flex the leg at the knee and to extend the thigh at the hip joint.

Gracilis

The gracilis is a long slender muscle located on the inner aspect of the thigh (figs. 1-28 and 1-29). It adducts the thigh, and flexes and medially rotates the leg. Its origin is in the symphysis pubis, and its insertion is in the medial surface of the tibia, below the condyle.

Sartorius

The sartorius is the longest muscle in the body. It extends diagonally across the front of the thigh from its origin at the ilium, down to its insertion near the tuberosity of the tibia (fig. 1-29). Its function is to flex the thigh and rotate it laterally, and to flex the leg and rotate it slightly medially.

Gastrocnemius and Soleus

The gastrocnemius and soleus (together commonly called the calf muscles) extend the foot at the ankle (figs. 1-28 and 1-29). The gastrocnemius originates at two points on the femur; the soleus originates at the head of the fibula and the medial border of the tibia. Both are inserted in a common tendon called the calcaneus, or Achilles tendon.

Tibialis Anterior

The tibialis anterior originates at the upper half of the tibia and inserts at the first metatarsal and cuneiform bones (fig. 1-28). It flexes the foot.

Diaphragm

The diaphragm (not shown) is an internal (as opposed to superficial) muscle that forms the floor of the thoracic cavity and the ceiling of the abdominal cavity. It is the primary muscle of respiration, modifying the size of the thorax and abdomen vertically. It has three openings for the passage of nerves and blood vessels.

THE INTEGUMENTARY SYSTEM

LEARNING OBJECTIVE: *Identify skin, its functions, structure, and appendages.*

Organ systems are comprised of tissues grouped together to form organs, and groups of organs with specialized functions. Since the skin acts with hair follicles, sebaceous glands, and sweat glands, these organs together constitute the integumentary system.

SKIN FUNCTION

The skin covers almost every visible part of the human body. Even the hair and nails are outgrowths from it. It protects the underlying structures from injury and invasion by foreign organisms; it contains the peripheral endings of many sensory nerves; and it has limited excretory and absorbing powers. The skin also plays an important part in regulating body temperature. In addition, the skin is a waterproof covering that prevents excessive water loss, even in very dry climates.

SKIN STRUCTURE

The skin, or integument, consists of two layers, the epidermis and the dermis, and supporting structures and appendages (fig. 1-30).

Epidermis

The epidermis is the outer skin layer (fig. 1-30). It is made up of tough, flat, scalelike epithelial cells. Five sublayers or strata of epidermal cells have been identified, and, listed from superficial to deep, they are

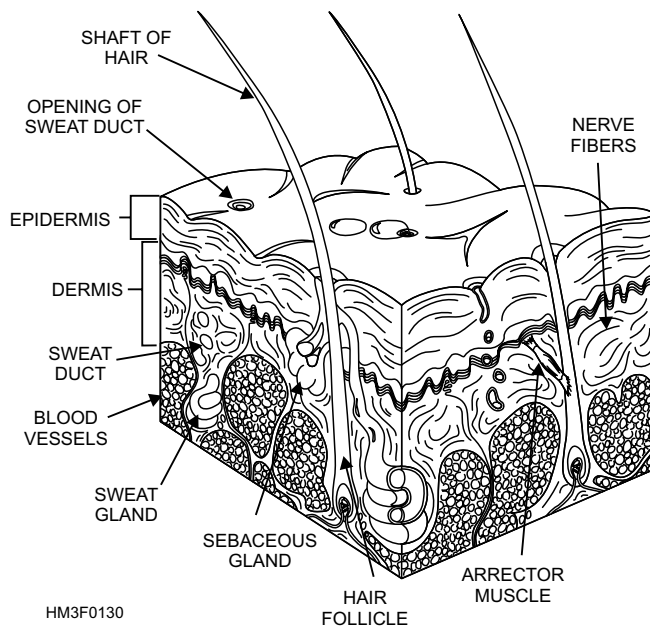


Figure 1-30.—Cross section of the skin.

the **stratum corneum**, **stratum lucidum** (not always present), **stratum granulosum**, **stratum spinosum**, and **stratum basale**.

Dermis

The dermis, or true skin, lies below the epidermis and gradually blends into the deeper tissues (fig. 1-30). It is a wide area of connective tissue that contains blood vessels, nerve fibers, smooth muscles, and skin appendages.

BLOOD VESSELS.—The blood vessels of the dermis can dilate to contain a significant portion of the body's blood supply (fig. 1-30). This ability, along with the actions of the sweat glands, forms the body's primary temperature-regulating mechanism. The constriction or dilation of these blood vessels also affects blood pressure and the volume of blood available to the internal organs.

NERVE FIBERS.—The skin contains two types of nerve fibers that carry impulses to and from the central nervous system (fig. 1-30). The nerve fibers are distributed to the smooth muscles in the walls of the arteries in the dermis and to the smooth muscles around the sweat glands and hair roots. The first type of nerve fiber carries impulses to the dermal muscles and glands, while the other type carries impulses from sensory receptors (i.e., detecting touch). Both nerve fibers send messages about the external environment to the brain.

SMOOTH MUSCLES.—Smooth involuntary muscles are found in the dermis. They are responsible for controlling the skin surface area. When dilated, these muscles allow for maximum skin surface exposure to aid heat loss. When constricted, the skin surface exposure is decreased, thus impeding heat radiation. Repeated muscle contractions (shivering) are also a rapid means of generating body heat.

Skin Appendages

The appendages of the skin are the nails, hairs, sebaceous glands, sweat glands, and ceruminous glands.

NAILS.—The nails are composed of horny epidermal scales and are found on the dorsal surfaces of the fingers and toes. They protect the many sensitive nerve endings at the ends of these digits. New formation of nail will occur in the epithelium of the nail bed. As a new nail is formed, the whole nail moves forward, becoming longer.

HAIR.—Hair is an epithelial structure found on almost every part of the surface of the body (fig. 1-30). Its color depends on the type of melanin present. The hair has two components: the root below the surface and the shaft projecting above the skin. The root is embedded in a pit-like depression called the hair follicle. Hair grows as a result of the division of the cells of the root. A small muscle, known as the **arrector** (fig. 1-30), fastens to the side of the follicle and is responsible for the gooseflesh appearance of the skin as a reaction to cold or fear. Each hair follicle is associated with two or more sebaceous glands.

SEBACEOUS GLANDS.—Sebaceous glands are found in most parts of the skin except in the soles of the feet and the palms of the hand (fig. 1-30). Their ducts open most frequently into the hair follicles and secrete an oily substance that lubricates the skin and hair, keeping them soft and pliable and preventing bacterial invasion.

SWEAT GLANDS.—Sweat glands are found in almost every part of the skin (fig. 1-30). They are control mechanisms to reduce the body's heat by evaporating water from its surface. The perspiration secreted is a combination of water, salts, amino acids, and urea. Normally, about one liter of this fluid is excreted daily. However, the amount varies with atmospheric temperature and humidity and the amount of exercise taken. When the outside temperature is high, or upon exercise, the glands secrete large amounts to cool the body through evaporation. When

evaporation does not remove all the sweat that has been excreted, the sweat collects in beads on the surface of the skin.

CERUMINOUS GLANDS.—Ceruminous glands are modified sweat glands found only in the auditory canal. They secrete a yellow, waxy substance called **cerumen** that protects the eardrum.

THE CIRCULATORY SYSTEM

LEARNING OBJECTIVE: *Identify the parts of the circulatory system, and recognize their major components and functions.*

The circulatory system, also called the **vascular system**, consists of blood, heart, and blood vessels. The circulatory system is close circuited (i.e., there is no opening to external environment of the body). The function of this system is to move blood between the cells and the organs of the integumentary, digestive, respiratory, and urinary system that communicate with the external environment of the body. This function is facilitated by the heart pumping blood through blood vessels. The blood travels throughout the body transporting nutrients and wastes, and permitting the exchange of gases (carbon dioxide and oxygen).

BLOOD

Blood is fluid tissue composed of formed elements (i.e., cells) suspended in plasma. It is pumped by the heart through arteries, capillaries, and veins to all parts of the body. Total blood volume of the average adult is 5 to 6 liters.

Plasma

Plasma is the liquid part of blood (fig. 1-31). Plasma constitutes 55 percent of whole blood (plasma and cells). It is a clear, slightly alkaline, straw-colored liquid consisting of about 92 percent water. The remainder is made up mainly of proteins. One of these proteins, **fibrinogen**, contributes to coagulation.

Blood Cells

The blood cells suspended in the plasma constitute 45 percent of whole blood. Its cells, which are formed mostly in red bone marrow, include red blood cells (RBCs) and white blood cells (WBCs). The blood also contains cellular fragments called blood platelets.

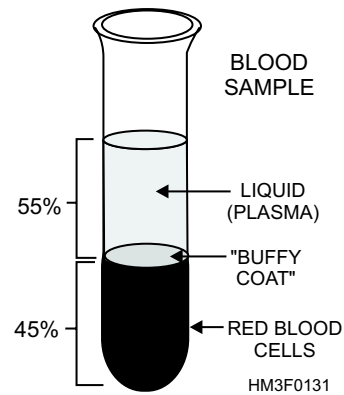


Figure 1-31.—Blood sample illustrating blood components.

When blood components are separated, the WBCs and platelets form a thin layer, called the **buffy coat**, between the layers of plasma and RBCs. These layers are illustrated in figure 1-31.

RED BLOOD CELLS.—Red blood cells, or **erythrocytes**, are small, biconcave, nonnucleated disks, formed in the red bone marrow (fig. 1-32). Blood of the average man contains 5 million red cells per cubic millimeter. Women have fewer red cells, 4.5 million per cubic millimeter. Emotional stress, strenuous exercise, high altitudes, and some diseases may cause an increase in the number of RBCs.

During the development of the red blood cell, a substance called **hemoglobin** is combined with it. Hemoglobin is the key of the red cell's ability to carry oxygen and carbon dioxide. Thus, the main function of erythrocytes is the transportation of respiratory gases. The red cells deliver oxygen to the body tissues, holding some oxygen in reserve for an emergency. Carbon dioxide is picked up by the same cells and discharged via the lungs.

The color of the red blood cell is determined by the hemoglobin content. Bright red (arterial) blood is due to the combination of oxygen and hemoglobin. Dark

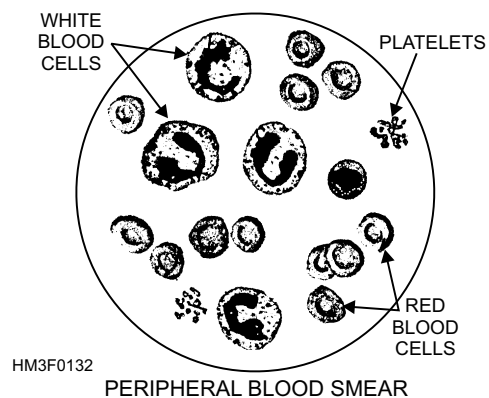


Figure 1-32.—A blood smear showing red blood cells, white blood cells, and platelets.

red (venous) blood is the result of hemoglobin combining with carbon dioxide.

Red blood cells live only about 100 to 120 days in the body. There are several reasons for their short life span. These delicate cells have to withstand constant knocking around as they are pumped into the arteries by the heart. These cells travel through blood vessels at high speed, bumping into other cells, bouncing off the walls of arteries and veins, and squeezing through narrow passages. They must adjust to continual pressure changes. The spleen is the “graveyard” where old, worn out cells are removed from the blood stream. Fragments of red blood cells are found in the spleen and other body tissues.

WHITE BLOOD CELLS.—White blood cells, or **leukocytes**, are almost colorless, nucleated cells originating in the bone marrow and in certain lymphoid tissues of the body (fig. 1-32). There is only one white cell to every 600 red cells. Normal WBC count is 6,000 to 8,000 per cubic millimeter, although the number of white cells may be 15,000 to 20,000 or higher during infection.

Leukocytes are important for the protection of the body against disease. Leukocytes can squeeze between the cells that form blood cell walls. This movement, called **diapedesis**, permits them to leave the blood stream through the capillary wall and attack pathogenic bacteria. They can travel anywhere in the body and are often named “the wandering cells.” They protect the body tissues by engulfing disease-bearing bacteria and foreign matter, a process called **phagocytosis**. When white cells are undermanned, more are produced, causing an increase in their number and a condition known as **leukocytosis**. Another way WBC's protect the body from disease is by producing **bacteriolysins** that dissolve the foreign bacteria. The secondary function of WBCs is to aid in blood clotting.

BLOOD PLATELETS.—Blood platelets, or **thrombocytes**, are irregular- or oval-shaped discs in the blood that contain no nucleus, only cytoplasm (fig. 1-32). They are smaller than red blood cells and average about 250,000 per cubic millimeter of blood. Blood platelets play an important role in the process of blood coagulation, clumping together in the presence of jagged, torn tissue.

Blood Coagulation

To protect the body from excessive blood loss, blood has its own power to coagulate, or clot. If blood components and linings of vessels are normal,

circulating blood will not clot. Once blood escapes from its vessels, however, a chemical reaction begins that causes it to become solid. Initially a blood clot is a fluid, but soon it becomes thick and then sets into a soft jelly that quickly becomes firm enough to act as a plug. This plug is the result of a swift, sure mechanism that changes one of the soluble blood proteins, **fibrinogen**, into an insoluble protein, **fibrin**, whenever injury occurs.

Other necessary elements for blood clotting are calcium salts; a substance called **prothrombin**, which is formed in the liver; blood platelets; and various factors necessary for the completion of the successive steps in the coagulation process. Once the fibrin plug is formed, it quickly enmeshes red and white blood cells and draws them tightly together. **Blood serum**, a yellowish clear liquid, is squeezed out of the clot as the mass shrinks. Formation of the clot closes the wound, preventing blood loss. A clot also serves as a network for the growth of new tissues in the process of healing. Normal clotting time is 3 to 5 minutes, but if any of the substances necessary for clotting are absent, severe bleeding will occur.

Hemophilia is an inherited disease characterized by delayed clotting of the blood and consequent difficulty in controlling hemorrhage. Hemophiliacs can bleed to death as a result of minor wounds.

THE HEART

The heart is a hollow, muscular organ, somewhat larger than the closed fist, located anteriorly in the chest and to the left of the midline. It is shaped like a cone, its base directed upward and to the right, the apex down and to the left. Lying obliquely in the chest, much of the base of the heart is immediately posterior to the sternum.

Heart Composition

The heart is enclosed in a membranous sac, the **pericardium**. The smooth surfaces of the heart and pericardium are lubricated by a serous secretion called **pericardial fluid**. The inner surface of the heart is lined with a delicate serous membrane, the **endocardium**, similar to and continuous with that of the inner lining of blood vessels.

The interior of the heart (fig. 1-33) is divided into two parts by a wall called the **interventricular septum**. In each half is an upper chamber, the **atrium**, which receives blood from the veins, and a lower chamber, the **ventricle**, which receives blood from the

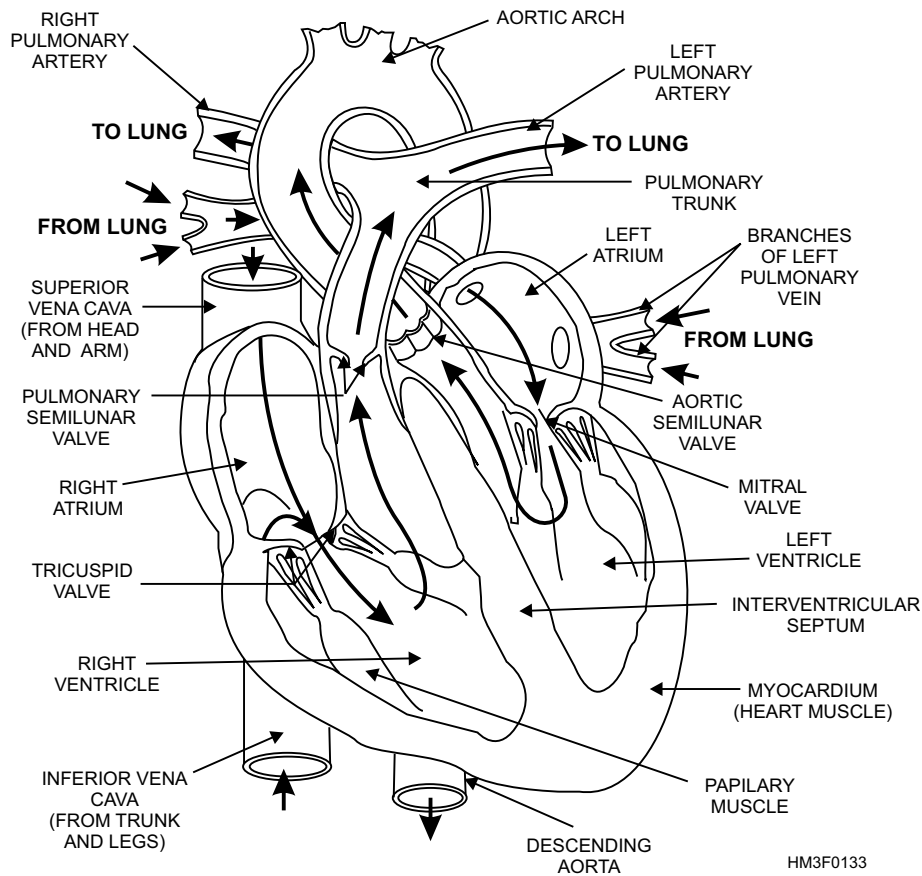


Figure 1-33.—Frontal view of the heart—arrows indicate blood flow.

atrium and pumps it out into the arteries. The openings between the chambers on each side of the heart are separated by flaps of tissue that act as valves to prevent backward flow of blood. The valve on the right has three flaps, or cusps, and is called the **tricuspid valve**. The valve on the left has two flaps and is called the **mitral**, or **bicuspid**, **valve**. The outlets of the ventricles are supplied with similar valves. In the right ventricle, the **pulmonary valve** is at the origin of the pulmonary artery. In the left ventricle, the **aortic valve** is at the origin of the aorta. See figure 1-33 for valve locations.

The heart muscle, the **myocardium**, is striated like the skeletal muscles of the body, but involuntary in action, like the smooth muscles. The walls of the atria are thin with relatively little muscle fiber because the blood flows from the atria to the ventricles under low pressure. However, the walls of the ventricles, which comprise the bulk of the heart, are thick and muscular. The wall of the left ventricle is considerably thicker than that of the right, because more force is required to pump the blood into distant or outlying locations of the circulatory system than into the lungs located only a short distance from the heart.

Heart Functions

The heart acts as four interrelated pumps. The right atrium receives deoxygenated blood from the body via the **superior** and **inferior vena cava**. It pumps the deoxygenated blood through the tricuspid valve to the right ventricle. The right ventricle pumps the blood past the pulmonary valve through the **pulmonary artery** to the lungs, where it is oxygenated. The left atrium receives the oxygenated blood from the lungs through four **pulmonary veins** and pumps it to the left ventricle past the mitral valve. The left ventricle pumps the blood to all areas of the body via the aortic valve and the **aorta**.

The heart's constant contracting and relaxing forces blood into the arteries. Each contraction is followed by limited relaxation or dilation. Cardiac muscle never completely relaxes: It always maintains a degree of tone. Contraction of the heart is called **systole** or “the period of work.” Relaxation of the heart is called **diastole** or “the period of rest.” A complete cardiac cycle is the time from onset of one contraction, or heart beat, to the onset of the next.

Cardiac Cycle

The cardiac cycle is coordinated by specialized tissues that initiate and distribute electrical (cardiac) impulses (fig. 1-34). The contractions of the heart are stimulated and maintained by the **sinoatrial (SA) node**, commonly called the **pacemaker** of the heart. The SA node is an elongated mass of specialized muscle tissue located in the upper part of the right atrium. The SA node sets off cardiac impulses, causing both atria to contract simultaneously. The normal heart rate, or number of contractions, is about 70 to 80 beats per minute.

This same cardiac impulse continues to travel to another group of specialized tissue called the **atrioventricular (AV) node**. The AV node is located in the floor of the right atrium near the septum that separates the atria. The cardiac impulse to the AV node is slowed down by **junctional fibers**. The junctional fibers conduct the cardiac impulse to the AV node; however, these fibers are very small in diameter, causing the impulse to be delayed. This slow arrival of the impulse to the AV node allows time for the atria to empty and the ventricles to fill with blood.

Once the cardiac impulse reaches the far side of the AV node, it quickly passes through a group of large fibers which make up the AV bundle (also called the bundle of His). The AV bundle starts at the upper part of the interventricular septum and divides into right and left branches. About halfway down the interventricular septum, the right and left branches

terminate into **Purkinje fibers**. The Purkinje fibers spread from the interventricular septum into the papillary muscles, which project inward from the ventricular walls. As the cardiac impulse passes through the Purkinje fibers, these fibers in turn stimulate the cardiac muscle of the ventricles. This stimulation of the cardiac muscles causes the walls of the ventricles to contract with a twisting motion. This action squeezes the blood out of the ventricular chambers and forces it into the arteries. This is the conclusion of one cardiac cycle.

Blood Pressure

Blood pressure is the pressure the blood exerts on the walls of the arteries. The highest pressure is called **systolic** pressure, because it is caused when the heart is in systole, or contraction. A certain amount of blood pressure is maintained in the arteries even when the heart is relaxed. This pressure is the **diastolic** pressure, because it is present during diastole, or relaxation of the heart. The difference between systolic and diastolic pressure is known as **pulse pressure**.

Normal blood pressure can vary considerably with an individual's age, weight, and general condition. For young adults, the systolic pressure is normally between 120 and 150 mm of mercury, and the diastolic pressure is normally between 70 and 90 mm of mercury. On average, women have lower blood pressure than men.

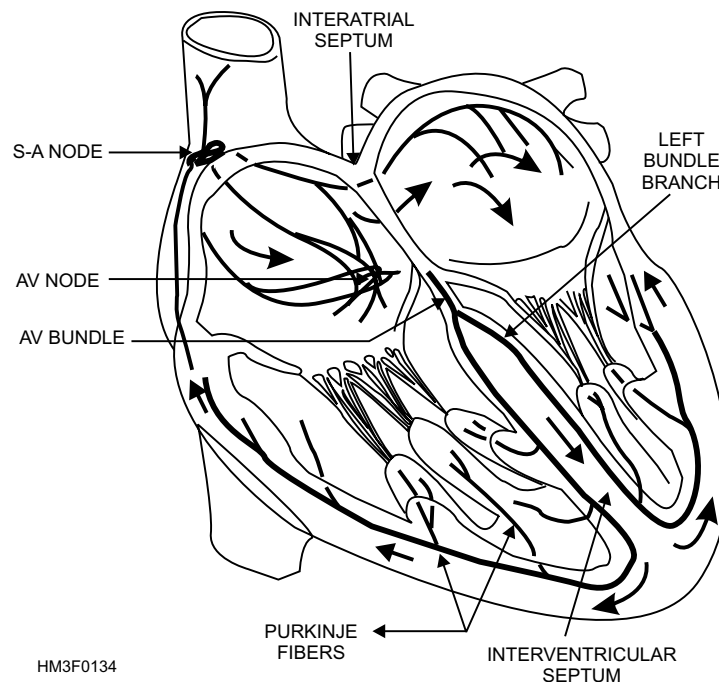


Figure 1-34.—Cardiac cycle.

BLOOD VESSELS

Blood vessels form a closed circuit of tubes that transport blood between the heart and body cells. The several types of blood vessels include arteries, arterioles, capillaries, venules, and veins.

Blood Vessel Classifications

The blood vessels of the body fall into three classifications:

- **Arteries and arterioles**—distributors
- **Capillaries**—exchangers
- **Veins and venules**—collectors

Arteries and Arterioles

Arteries are elastic tubes constructed to withstand high pressure. They carry blood away from the heart to all parts of the body. The smallest branches of the arteries are called **arterioles**. The walls of arteries and arterioles consist of layers of endothelium, smooth muscle, and connective tissue. The smooth muscles of arteries and arterioles constrict and dilate in response to electrical impulses received from the autonomic nervous system.

Capillaries

At the end of the arterioles is a system of minute vessels that vary in structure, but which are spoken of collectively as capillaries. It is from these capillaries that the tissues of the body are fed. There are approximately 60,000 miles of capillaries in the body. As the blood passes through the capillaries, it releases oxygen and nutritive substances to the tissues and takes up various waste products to be carried away by **venules**. Venules continue from capillaries and merge to form veins.

Veins and Venules

Veins and venules form the venous system. The venous system is comprised of vessels that collect blood from the capillaries and carry it back to the heart. Veins begin as tiny venules formed from the capillaries. Joining together as tiny rivulets, veins connect and form a small stream. The force of muscles contracting adjacent to veins aids in the forward propulsion of blood on its return to the heart. Valves, spaced frequently along the larger veins, prevent the backflow of blood. The walls of veins are similar to

arteries, but are thinner and contain less muscle and elastic tissue.

Arterial System

Arterial circulation is responsible for taking freshly oxygenated blood from the heart to the cells of the body (fig. 1-35). To take this oxygenated blood from the heart to the entire body, the arterial system begins with the contraction of blood from the left ventricle into the aorta and its branches.

AORTA.—The aorta, largest artery in the body, is a large tube-like structure arising from the left ventricle of the heart. It arches upward over the left lung and then down along the spinal column through the thorax and the abdomen, where it divides and sends arteries down both legs (fig. 1-35).

KEY BRANCHES OF THE AORTA.—Key arterial branches of the aorta are the coronary, innominate (brachiocephalic), left common carotid, and left subclavian. The coronary arteries are branches of what is called the **ascending aorta**. The coronary arteries supply the heart with blood. There are three large arteries that arise from the aorta as it arches over the left lung. First is the **innominate artery**, which divides into the **right subclavian artery** to supply the right arm, and the **right common carotid** to supply the right side of the head. The second branch is the **left common carotid**, which supplies the left side of the head. The third branch is the **left subclavian**, which supplies the left arm.

ARTERIES OF THE HEAD, NECK, AND BRAIN.—The **carotid arteries** divide into internal and external branches, the external supplying the muscle and skin of the face and the internal supplying the brain and the eyes.

ARTERIES OF THE UPPER EXTREMITIES.—The **subclavian arteries** are so named because they run underneath the clavicle. They supply the upper extremities, branching off to the back, chest, neck, and brain through the spinal column (fig. 1-35).

The large artery going to the arm is called the **axillary**. The axillary artery becomes the **brachial artery** as it travels down the arm and divides into the **ulnar** and **radial arteries**. The radial artery is the artery at the wrist that you feel when you take the pulse of your patient (fig. 1-35).

ARTERIES OF THE ABDOMEN.—In the abdomen, the aorta gives off branches to the abdominal viscera, including the stomach, liver, spleen, kidneys,

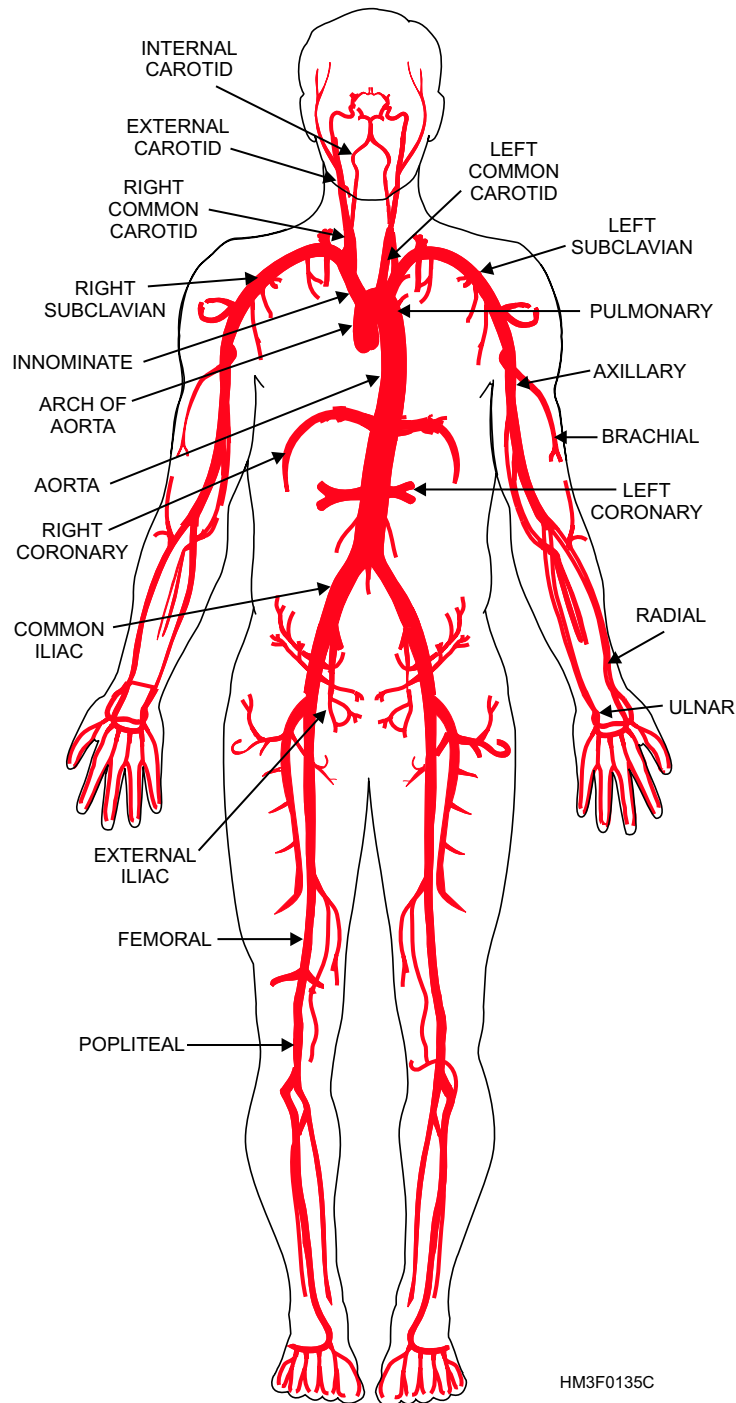


Figure 1-35.—Principal vessels of the arterial system.

and intestines. The aorta later divides into the **left and right common iliacs**, which supply the lower extremities (fig. 1-35).

ARTERIES OF THE LOWER EXTREMITIES.—The left and right common iliacs, upon entering the thigh, become the **femoral artery**. At the knee, this same vessel is named the **popliteal artery** (fig. 1-35).

Venous System

Venous circulation is responsible for returning the blood to the heart after exchanges of gases, nutrients, and wastes have occurred between the blood and body cells (fig. 1-36). To return this blood to the heart for reoxygenation, the venous system begins with the merging of capillaries into venules, venules into small veins, and small veins into larger veins. The blood vessel paths of the venous system are difficult to

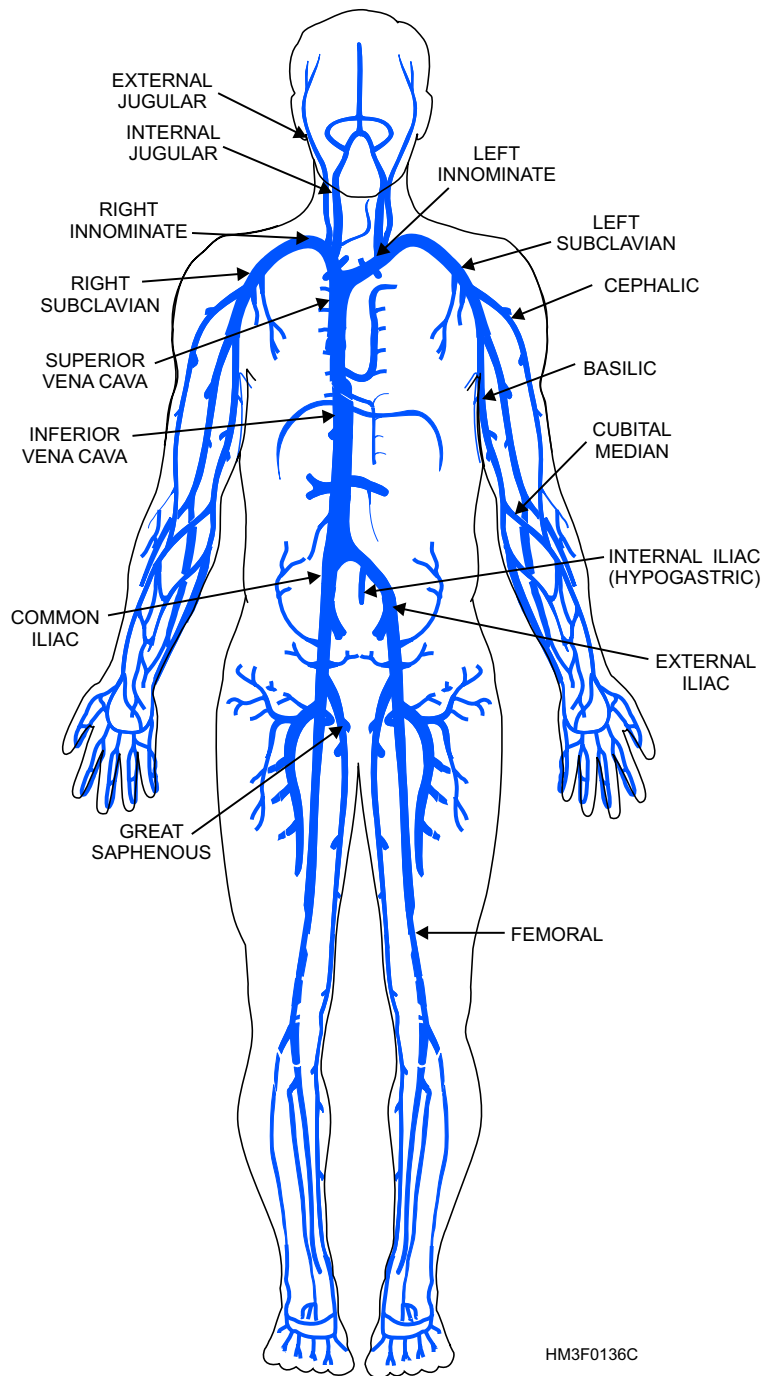


Figure 1-36.—Principal vessels of the venous system.

follow, unlike the arterial system. However, the larger veins are commonly located parallel to the course taken by their counterpart in the arterial system. For instance, the renal vein parallels the renal artery, the common iliac vein parallels the common iliac artery, and so forth.

THREE PRINCIPAL VENOUS SYSTEMS.—

The three principal venous systems in the body are the **pulmonary**, **portal**, and **systemic**.

- The **pulmonary system** is composed of four vessels, two from each lung, which empty into the left atrium. These are the only veins in the body that carry freshly oxygenated blood.

- The **portal system** consists of the veins that drain venous blood from the abdominal part of the digestive tract—the spleen, pancreas, and gallbladder, but not the lower rectum—and deliver it to the liver. There, it is distributed by a set of venous capillaries. The blood in the portal system conveys absorbed substances from the intestinal tract to the liver for storage,

alteration, or detoxification. From the liver the blood flows through the hepatic vein to the inferior vena cava.

- The **systemic system** is divided into the deep and superficial veins. The superficial veins lie immediately under the skin, draining the skin and superficial structures. The deep veins, usually located in the muscle or deeper layers, drain the large muscle masses and various other organs. Deep veins commonly lie close to the large arteries that supply the various organs of the body and typically have the same name as the artery they accompany.

VEINS OF THE HEAD, NECK, AND BRAIN.—The superficial veins of the head unite to form the **external jugular veins**. The external jugular veins drain blood from the scalp, face, and neck, and finally empty into the **subclavian veins**.

The veins draining the brain and internal facial structures are the **internal jugular veins**. These combine with the subclavian veins to form the **innominate veins**, which empty into the **superior vena cava** (fig. 1-36).

VEINS OF THE UPPER EXTREMITIES.—The veins of the upper extremities begin at the hand and extend upward. A vein of great interest to you is the **median cubital**, which crosses the anterior surface of the elbow. It is the vein most commonly used for venipuncture. Also found in this area are the **basilic** and **cephalic veins**, which extend from the midarm to the shoulder.

The deep veins of the upper arm unite to form the **axillary vein**, which unites with the superficial veins to form the subclavian vein. This vein later unites with other veins to form the innominate and eventually, after union with still more veins, the superior vena cava (fig. 1-36).

VEINS OF THE ABDOMEN AND THORACIC REGION.—The veins from the abdominal organs, with the exception of those of the portal system, empty directly or indirectly into the **inferior vena cava**, while those of the thoracic region eventually empty into the superior vena cava (fig. 1-36).

VEINS OF THE LOWER EXTREMITIES.—In the lower extremities (fig. 1-36), a similar system drains the superficial areas. The **great saphenous vein** originates on the inner aspect of the foot and extends up the inside of the leg and thigh to join the **femoral vein** in the upper thigh. The great saphenous vein is used for intravenous injections at the ankle.

The veins from the lower extremities unite to form the femoral vein in the thigh, which becomes the **external iliac vein** in the groin. Higher in this region, external iliac unites the **internal iliac** (hypogastric) **vein** from the lower pelvic region to form the **common iliac veins**. The right and left common iliac veins unite to form the inferior vena cava.

THE LYMPHATIC SYSTEM

LEARNING OBJECTIVE: *Identify the parts of the lymphatic system and their function.*

All tissue cells of the body are continuously bathed in **interstitial fluid**. This fluid is formed by leakage of blood plasma through minute pores of the capillaries. There is a continual interchange of fluids of the blood and tissue spaces with a free interchange of nutrients and other dissolved substances. Most of the tissue fluid returns to the circulatory system by means of capillaries, which feed into larger veins. Large protein molecules that have escaped from the arterial capillaries cannot reenter the circulation through the small pores of the capillaries. However, these large molecules, as well as white blood cells, dead cells, bacterial debris, infected substances, and larger particulate matter, can pass through the larger pores of the lymphatic capillaries and, thus, enter the lymphatic circulatory system with the remainder of the tissue fluid.

The lymphatic system also helps defend the tissues against infections by supporting the activities of the **lymphocytes**, which give immunity, or resistance, to the effects of specific disease-causing agents.

PATHWAYS OF THE LYMPHATIC SYSTEM

The lymphatic pathway begins with lymphatic capillaries. These small tubes merge to form lymphatic vessels, and the lymphatic vessels in turn lead to larger vessels that join with the veins in the thorax.

Lymphatic Capillaries

Lymphatic capillaries are closed-ended tubes of microscopic size (fig. 1-37). They extend into interstitial spaces, forming complex networks that parallel blood capillary networks. The lymphatic capillary wall consists of a single layer of squamous epithelial cells. This thin wall makes it possible for interstitial fluid to enter the lymphatic capillary. Once

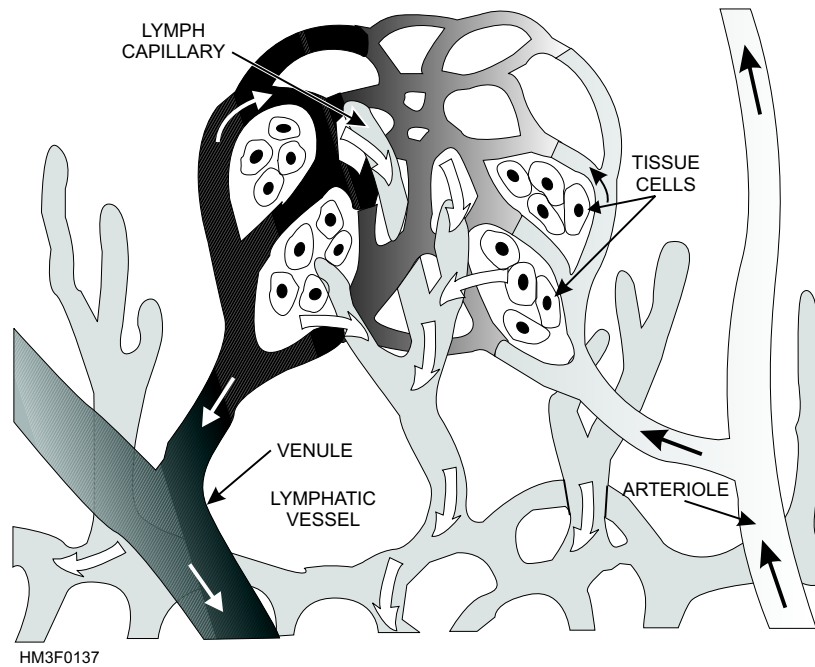


Figure 1-37.—Lymphatic capillary and vessel.

the interstitial fluid enters the lymphatic capillaries, the fluid is called **lymph**.

Lymphatic Vessels

Lymphatic vessels are formed from the merging of lymphatic capillaries (fig. 1-37). Lymphatic vessels, also known simply as **lymphatics**, are similar to veins in structure. The vessel walls are composed of three layers: an inner layer of endothelial tissue, a middle layer of smooth muscle and elastic fibers, and an outer layer of connective tissue. Like a vein, the lymphatic vessel has valves to prevent backflow of lymph. The larger lymphatic vessels lead to specialized organs called lymph nodes. After leaving these structures, the vessels merge to form still larger lymphatic trunks.

Lymphatic Trunks and Ducts

Lymphatic trunks drain lymph from large regions in the body. The lymphatic trunks are usually named after the region they serve, such as the subclavian trunk that drains the arm. There are many lymphatic trunks throughout the body. These lymphatic trunks then join one of two collecting ducts, the **thoracic duct** and the **right lymphatic duct** (fig. 1-38).

Lymphatic trunks from the upper half of the right side of the body converge to form the right lymphatic duct, which empties into the right subclavian vein. Drainage from the remainder of the body is by way of the thoracic duct, which empties into the left subclavian vein.

LYMPH NODES

Lymph nodes, which are frequently called glands but are not true glands, are small bean-shaped bodies of lymphatic tissue found in groups of two to fifteen along the course of the lymph vessels (fig. 1-38). Major locations of lymph nodes are in the following regions: cervical, axillary, inguinal, pelvic cavity, abdominal cavity, and thoracic cavity. Lymph nodes vary in size and act as filters to remove bacteria and particles from the lymph stream. Lymph nodes produce lymphocytes, which help defend the body against harmful foreign particles, such as bacteria, cells, and viruses. Lymph nodes also contain **macrophages**, which engulf and destroy foreign substances, damaged cells, and cellular debris.

THE RESPIRATORY SYSTEM

LEARNING OBJECTIVE: *Identify the location and function of each part of the respiratory system, and recall the process of respiration.*

Respiration is the exchange of oxygen and carbon dioxide between the atmosphere and the cells of the body. There are two phases of respiration:

- **Physical, or mechanical, respiration** involves the motion of the diaphragm and rib cage. The

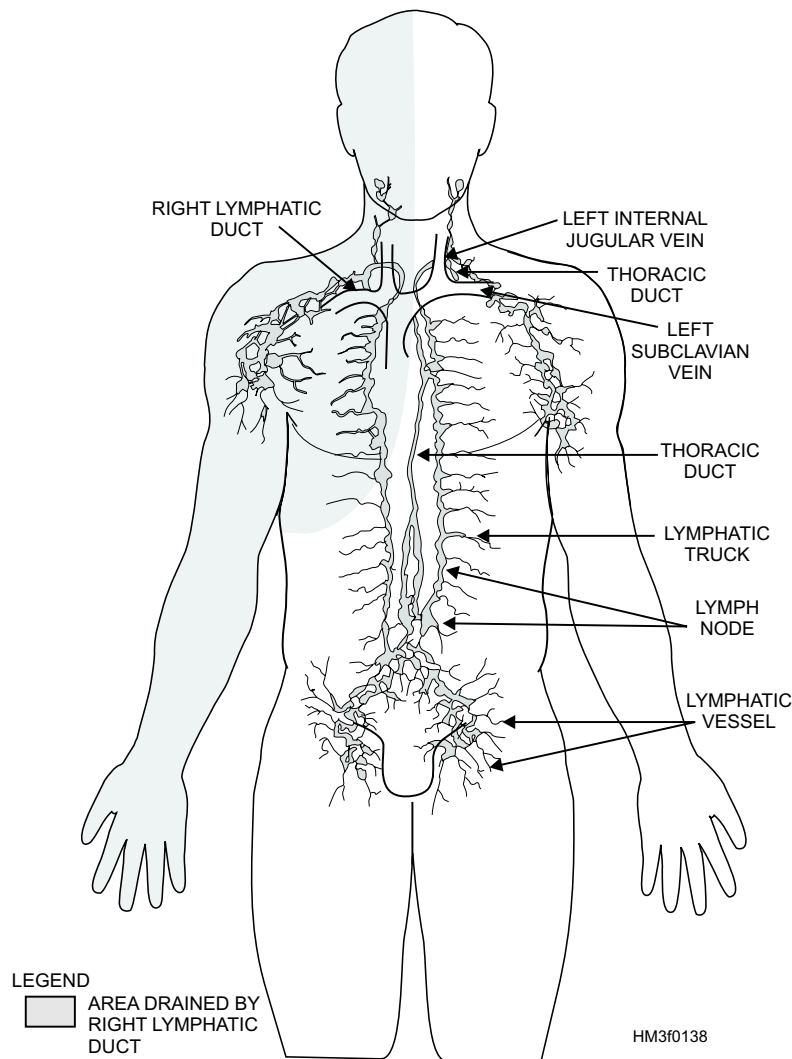


Figure 1-38.—Pathway of right lymphatic duct and thoracic duct.

musculoskeletal action, which resembles that of a bellows, causes air to be inhaled or exhaled.

- **Physiological respiration** involves an exchange of gases, oxygen and carbon dioxide, at two points in the body. The first is the transfer that occurs in the lungs between the incoming oxygen and the carbon dioxide present in the capillaries of the lungs (external respiration). The second transfer occurs when oxygen brought into the body replaces carbon dioxide build up in the cellular tissue (internal respiration).

Normally, oxygen and carbon dioxide exchange in equal volumes; however, certain physiological conditions may throw this balance off. For example, heavy smokers will find that the ability of their lungs to exchange gases is impaired, leading to shortness of breath and fatigue during even slight physical exertion. This debilitating situation is the direct result of their inability to draw a sufficient amount of oxygen into the body to replace the carbon dioxide build-up and

sustain further muscular exertion. On the other hand, hyperventilation brings too much oxygen into the body, overloading the system with oxygen, and depleting the carbon dioxide needed for balance.

ANATOMY OF THE RESPIRATORY SYSTEM

Air enters the nasal chambers and the mouth, then passes through the pharynx, larynx, trachea, and bronchi into the bronchioles. Each bronchiole is surrounded by a cluster of alveoli (fig. 1-39).

Nasal Cavity

Air enters the nasal cavity through the nostrils (**nares**). Lining the nasal passages are hairs, which, together with the mucous membrane, entrap and filter out dust and other minute particles that could irritate the lungs. Incoming air is warmed and moistened in the

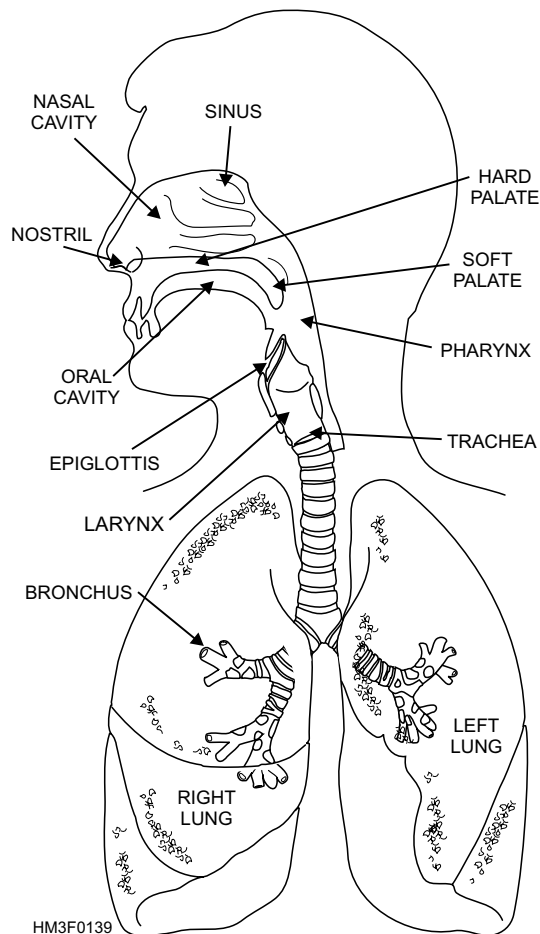


Figure 1-39.—Organs of the respiratory system.

chambers of the nasal cavity to prevent damage to the lungs. The nasal and oral cavities are separated by the **palate**. The anterior, rigid portion is called the **hard palate**, and the posterior fleshy part is called the **soft palate**. The mouth and nose serve as secondary respiratory structures.

Pharynx

The pharynx, or throat, serves both the respiratory and digestive systems and aids in speech. It has a mucous membrane lining that traps microscopic particles in the air and aids in adjusting temperature and humidifying inspired (inhaled) air. The pharynx connects with the mouth and nasal chambers posteriorly. According to its location, the pharynx is referred to as the **nasopharynx** (posterior to the nasal chambers), the **oropharynx** (posterior to the mouth), or the **laryngopharynx** (posterior to the pharynx).

Epiglottis

The epiglottis is a lidlike, cartilaginous structure that covers the entrance to the larynx and separates it

from the pharynx. It acts as a trap door to deflect food particles and liquids from the entrance to the larynx and trachea.

Larynx

The larynx, or voice box, is a triangular cartilaginous structure located between the tongue and the trachea. It is protected anteriorly by the thyroid cartilage (commonly called the Adam's apple), which is usually larger and more prominent in men than in women. During the act of swallowing, it is pulled upward and forward toward the base of the tongue. The larynx is responsible for the production of vocal sound (voice). This sound production is accomplished by the passing of air over the vocal cords. The ensuing vibrations can be controlled to produce the sounds of speech or singing. The nose, mouth, throat, bone sinuses, and chest serve as resonating chambers to further refine and individualize the voice.

Trachea

The trachea, or windpipe, begins at the lower end of the larynx and terminates by dividing into the right and left bronchi. It is a long tube composed of 16 to 20 C-shaped cartilaginous rings, embedded in a fibrous membrane, that support its walls, preventing their collapse (fig. 1-39).

The trachea has a ciliated mucous membrane lining that entraps dust and foreign material. It also propels secretions and exudates from the lungs to the pharynx, where they can be expectorated.

Bronchi

The bronchi are the terminal branches of the trachea, which carry air to each lung and further divide into the bronchioles.

Bronchioles

The bronchioles are much smaller than the bronchi and lack supporting rings of cartilage. They terminate at the alveoli (fig. 1-40).

Alveoli

The alveoli are thin, microscopic air sacs within the lungs (fig. 1-40). They are in direct contact with the pulmonary capillaries. It is here that fresh oxygen exchanges with carbon dioxide by means of a diffusion process through the alveolar and capillary cell walls

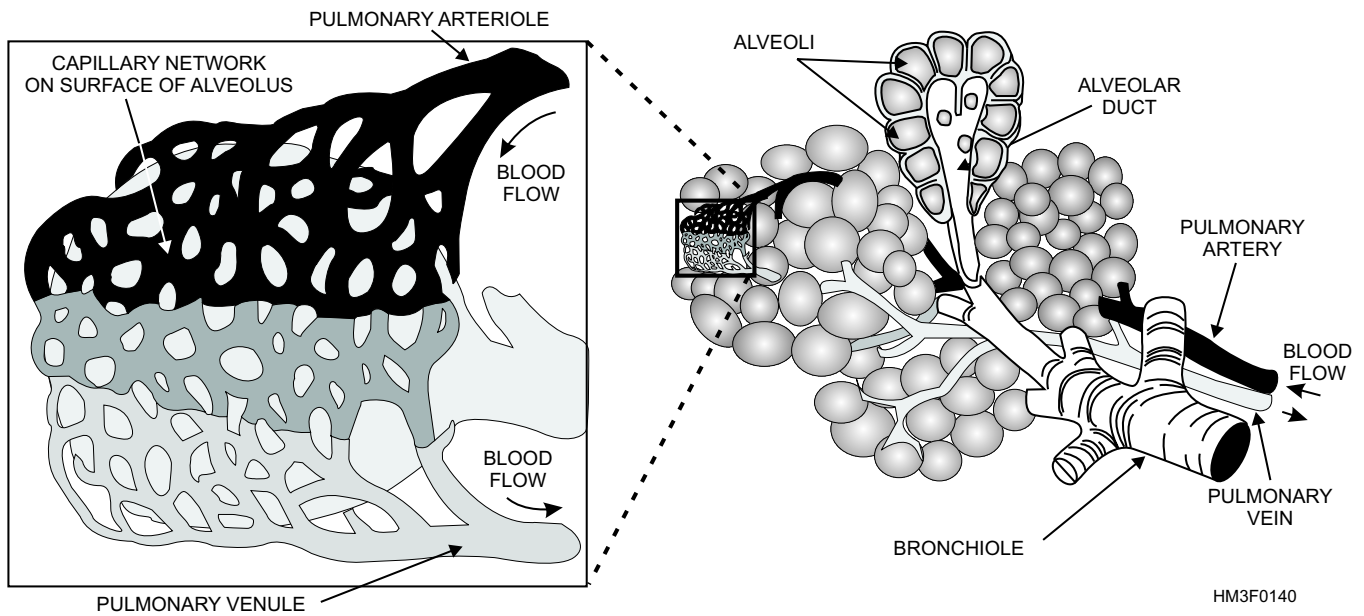


Figure 1-40.—Bronchiole and alveoli.

(fig. 1-41). The **lungs** are cone-shaped organs that lie in the thoracic cavity. Each lung contains thousands of alveoli with their capillaries. The right lung is larger than the left lung and is divided into superior, middle, and inferior lobes. The left lung has two lobes, the superior and the inferior.

Pleurae

The pleurae are airtight membranes that cover the outer surface of the lungs and line the chest wall. They secrete a serous fluid that prevents friction during movements of respiration.

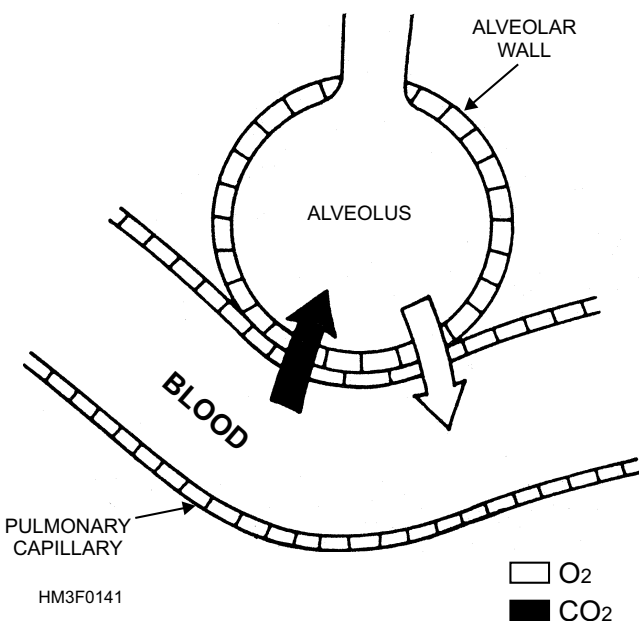


Figure 1-41.—Pulmonary exchange at alveolus.

Mediastinum

The mediastinum is the tissue and organs of the thoracic cavity that form a septum between the lungs. It extends from the sternum to the thoracic vertebrae and from the fascia of the neck to the diaphragm. The mediastinum contains the heart, the great blood vessels, the esophagus, a portion of the trachea, and the primary bronchi.

Diaphragm

The diaphragm is the primary muscle of respiration. It is a dome-shaped muscle and separates the thoracic and abdominal cavities. Contraction of this muscle flattens the dome and expands the vertical diameter of the chest cavity.

Intercostal Muscles

The intercostal muscles are situated between the ribs. Their contraction pulls the ribs upward and outward, resulting in an increase in the transverse diameter of the chest (chest expansion).

Inhalation is the direct result of the expansion caused by the action of the diaphragm and intercostal muscles. The increase in chest volume creates a negative (lower than atmospheric) pressure in the pleural cavity and lungs. Air rushes into the lungs through the mouth and nose to equalize the pressure. **Exhalation** results when the muscles of respiration relax. Pressure is exerted inwardly as muscles and

bones return to their normal position, forcing air from the lungs.

THE PROCESS OF RESPIRATION

The rhythmical movements of breathing are controlled by the respiratory center in the brain. Nerves from the brain pass down through the neck to the chest wall and diaphragm. The nerve that controls the diaphragm is called the **phrenic nerve**; the nerve that controls the larynx is the **vagus nerve**; and the nerves that control the muscles between the ribs are the **intercostal nerves**.

The respiratory center is stimulated by chemical changes in the blood. When too much carbon dioxide accumulates in the blood stream, causing the blood to become acidic, the respiratory center signals the lungs to breathe faster to get rid of the carbon dioxide.

The respiratory center can also be stimulated or depressed by a signal from the brain. For example, changes in one's emotional state can alter respiration through laughter, crying, emotional shock, or panic.

The muscles of respiration normally act automatically, with normal respiration being 14 to 18 cycles per minute. The lungs, when filled to capacity, hold about 6,500 ml of air, but only 500 ml of air is exchanged with each normal respiration. This exchanged air is called **tidal air**. The amount of air left in the lungs after forceful exhalation is about 1,200 ml and is known as **residual air**.

THE NERVOUS SYSTEM

LEARNING OBJECTIVE: *Identify the components and function of a neuron, recall the process of impulse transmission, and identify the components and functions of the central and peripheral nervous systems.*

The activities of the widely diverse cells, tissues, and organs of the body must be monitored, regulated, and coordinated to effectively support human life. The interaction of the nervous and endocrine systems provides the needed control.

The nervous system is specifically adapted to the rapid transmission of impulses from one area of the body to another. On the other hand, the endocrine system, working at a far slower pace, maintains body metabolism at a fairly constant level.

In this section, you will study the **neuron**, the basic functional unit of the nervous system. Also, you will study the components and functions of the different divisions of the nervous system. The nervous system is divided into two major groups, the **central nervous system (CNS)** and the **peripheral nervous system (PNS)**. Another division of the nervous system is the **autonomic nervous system (ANS)**, which is further subdivided into the **sympathetic** and **parasympathetic nervous systems**.

THE NEURON

The structure and functional unit of the nervous system is the nerve cell, or neuron, which can be classified into three types. The first is the **sensory neuron**, which conveys sensory impulses inward from the receptors. The second is the **motor neuron**, which carries command impulses from a central area to the responding muscles or organs. The third type is the **interneuron**, which links the sensory neurons to the motor neurons.

The neuron is composed of dendrites, a cyton, and an axon (fig. 1-42). The **dendrites** are thin receptive branches, and vary greatly in size, shape, and number with different types of neurons. They serve as receptors, conveying impulses toward the **cyton**. The cyton is the cell body containing the nucleus. The single, thin extension of the cell outward from the cyton is called the **axon**. It conducts impulses away from the cyton to its **terminal branches**, which transmit the impulses to the dendrites of the next neuron.

Large axons of the peripheral nerves are commonly enclosed in a sheath, called **neurilemma**, composed of **Schwann cells** (fig. 1-42). Schwann cells wrap around the axon and act as an electrical insulator.

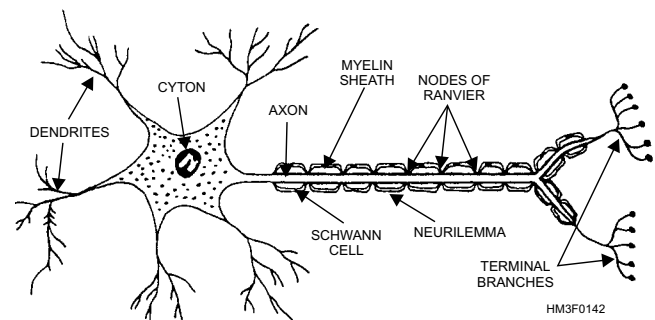


Figure 1-42.—The neuron and its parts.

The membranes of the Schwann cell are composed largely of a lipid-protein called **myelin**, which forms a **myelin sheath** on the outside of an axon. The myelin sheath has gaps between adjacent Schwann cells called **nodes of Ranvier**. Nerve cells without Schwann cells also lack myelin and neurilemma sheaths.

IMPULSE TRANSMISSION

When dendrites receive a sufficiently strong stimulus, a short and rapid change in electrical charge, or polarity, of the neuron is triggered. Sodium ions rush through the plasma membrane into the cell, potassium ions leave, and an electrical impulse is formed, which is conducted toward the cyton. The cyton receives the impulse and transmits it to the terminal filaments of the axon. At this point a chemical transmitter such as acetylcholine is released into the **synapse**, a space between the axon of the activated nerve and the dendrite receptors of another neuron. This chemical transmitter activates the next nerve. In this manner, the impulse is passed from neuron to neuron down the nerve line to a central area at approximately the speed of a bullet.

Almost immediately after being activated, the chemical transmitter in the synapse is neutralized by the enzyme acetylcholinesterase, and the first neuron returns to its normal state by pumping out the sodium ions and drawing potassium ions back in through the plasma membrane. When these actions are completed, the nerve is ready to be triggered again. A particularly strong stimulus will cause the nerve to fire in rapid succession, or will trigger many other neurons, thus giving a feeling of intensity to the perceived sensation.

NERVES

A nerve is a cordlike bundle of nerve fibers held together with connective tissue. Each nerve fiber is an extension of a neuron. Nerves that conduct impulses into the brain or the spinal cord are called **sensory nerves**, and those that carry impulses to muscles and glands are termed **motor nerves**. Most nerves, however, include both sensory and motor fibers, and they are called **mixed nerves**.

CENTRAL NERVOUS SYSTEM

The central nervous system (CNS) consists of the brain and spinal cord. The brain is almost entirely enclosed in the skull, but it is connected with the spinal cord, which lies in the canal formed by the vertebral column.

Brain

The brain has two main divisions, the **cerebrum** and the **cerebellum**. The cerebrum is the largest and most superiorly situated portion of the brain. It occupies most of the cranial cavity. The outer surface is called the **cortex**. This portion of the brain is also called “gray matter” because the nerve fibers are unmyelinated (not covered by a myelin sheath), causing them to appear gray. Beneath this layer is the **medulla**, often called the white matter of the brain because the nerves are myelinated (covered with a myelin sheath), giving them their white appearance.

CEREBRUM.—The cortex of the cerebrum is irregular in shape. It bends on itself in folds called **convolutions**, which are separated from each other by grooves, also known as **fissures**. The deep **sagittal cleft**, a longitudinal fissure, divides the cerebrum into two hemispheres. Other fissures further subdivide the cerebrum into lobes, each of which serves a localized, specific brain function (fig. 1-43). For example, the **frontal lobe** is associated with the higher mental processes such as memory, the **parietal lobe** is concerned primarily with general sensations, the **occipital lobe** is related to the sense of sight, and the **temporal lobe** is concerned with hearing.

CEREBELLUM.—The cerebellum is situated posteriorly to the brain stem (which is made up of the pons, mid-brain, and medulla oblongata) and inferior to the occipital lobe. The cerebellum is concerned chiefly with bringing balance, harmony, and coordination to the motions initiated by the cerebrum.

PONS AND MEDULLA OBLONGATA.—Two smaller divisions of the brain vital to life are the pons and the medulla oblongata. Together, the pons and medulla form the **brain stem** (fig. 1-43). The pons consists chiefly of a mass of white fibers connecting the other three parts of the brain (the cerebrum, cerebellum, and medulla oblongata).

The medulla oblongata is the inferior portion of the brain, the last division before the beginning of the spinal cord. It connects to the spinal cord at the upper level of the first cervical vertebra (C-1). In the medulla oblongata are the centers for the control of heart action, breathing, circulation, and other vital processes such as blood pressure.

MENINGES.—The outer surface of the brain and spinal cord is covered with three layers of membranes called the meninges. The **dura mater** is the strong outer layer; the **arachnoid membrane** is the delicate

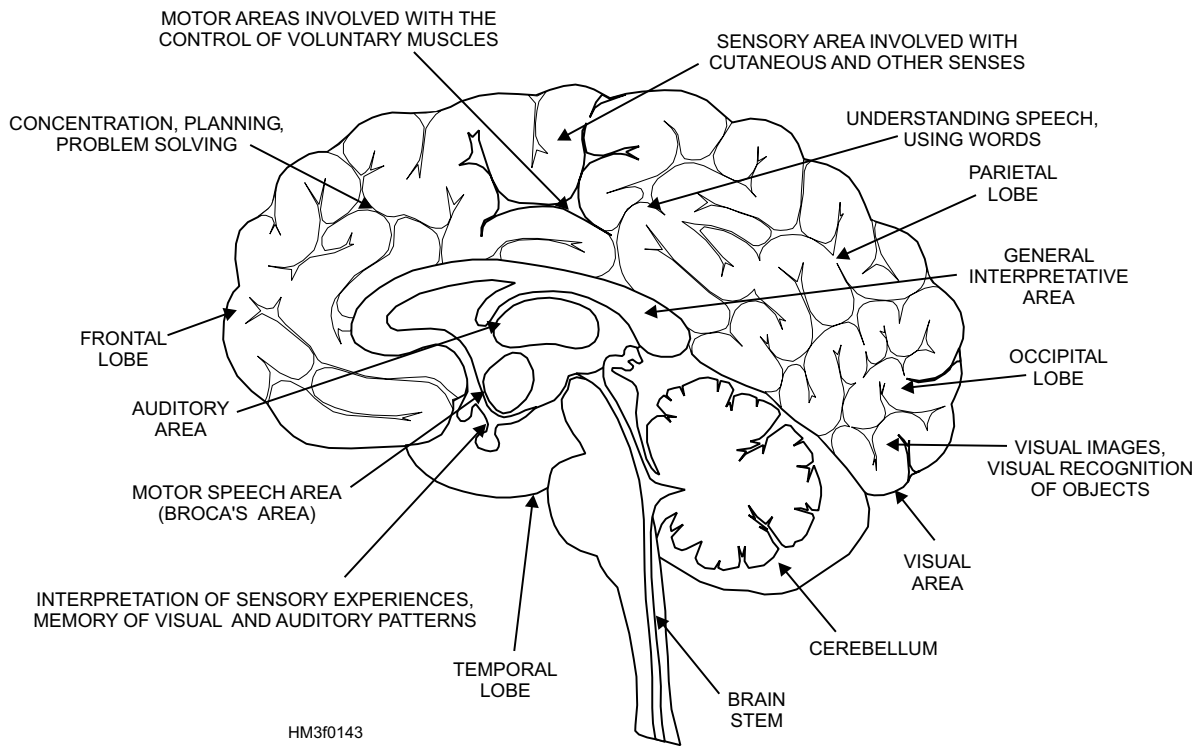


Figure 1-43.—Functional areas of the brain.

middle layer; and the **pia mater** is the vascular inner-most layer that adheres to the surface of the brain and spinal cord. Inflammation of the meninges is called meningitis. The type of meningitis contracted depends upon whether the brain, spinal cord, or both are affected, as well as whether it is caused by viruses, bacteria, protozoa, yeasts, or fungi.

CEREBROSPINAL FLUID.—Cerebrospinal fluid is formed by a plexus, or network, of blood vessels in the central ventricles of the brain. It is a clear, watery solution similar to blood plasma. The total quantity of spinal fluid bathing the spinal cord is about 75 ml. This fluid is constantly being produced and reabsorbed. It circulates over the surface of the brain and spinal cord and serves as a protective cushion as well as a means of exchange for nutrients and waste materials.

Spinal Cord

The spinal cord is continuous with the medulla oblongata and extends from the foramen magnum, through the atlas, to the lower border of the first lumbar vertebra, where it tapers to a point. The spinal cord is surrounded by the bony walls of the vertebral canal (fig. 1-44). Ensheathed in the three protective meninges and surrounded by fatty tissue and blood vessels, the cord does not completely fill the vertebral canal, nor does it extend the full length of it. The nerve

roots serving the lumbar and sacral regions must pass some distance down the canal before making their exit. The **sympathetic trunk** contains the **paravertebral ganglia** (*sing.* ganglion), knotlike masses of nerve cell bodies (fig. 1-44).

A cross section of the spinal cord shows white and gray matter (fig. 1-45). The outer white matter is composed of bundles of myelinated nerve fibers arranged in functionally specialized tracts. It establishes motor communication between the brain and the body parts. The inner gray unmyelinated

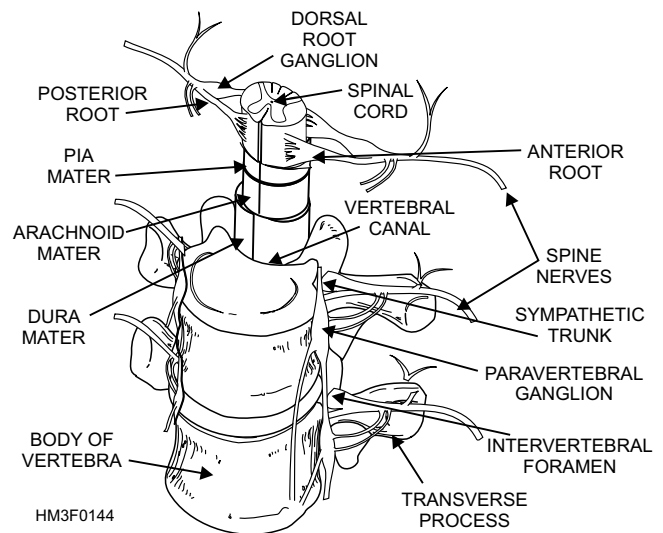


Figure 1-44.—Spinal cord.

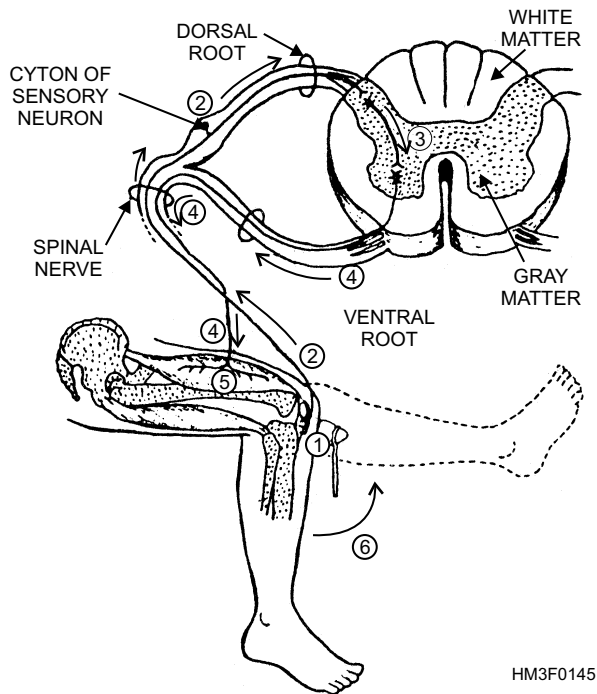


Figure 1-45.—Cross section of the spinal cord and reflex arc—arrows and numbers show impulse pathway.

matter is shaped roughly like the letter H. It establishes sensory communication between the brain and the spinal nerves, conducting sensory impulses from the body parts.

The spinal cord may be thought of as an electric cable containing many wires (nerves) that connect parts of the body with each other and with the brain. Sensations received by a sensory nerve are brought to the spinal cord, and the impulse is transferred either to the brain or to a motor nerve. The majority of impulses go to the brain for action. However, a system exists for quickly handling emergency situations. It is called the **reflex arc**.

If you touch a hot stove, you must remove your hand from the heat source immediately or the skin will burn very quickly. But the passage of a sense impulse to the brain and back again to a motor nerve takes too much time. The reflex arc responds instantaneously to emergency situations like the one just described. The sensation of heat travels to the spinal cord on a sensory nerve. When the sensation reaches the spinal cord, it is picked up by an interneuron in the gray matter. This reception then triggers the appropriate nerve to stimulate a muscle reflex drawing the hand away. An illustrated example of the reflex arc is shown in figure 1-45.

The reflex arc works well in simple situations requiring no action of the brain. Consider, however, what action is involved if the individual touching the stove pulls back and, in so doing, loses balance and has to grab a chair to regain stability. Then the entire spinal cord is involved. Additional impulses must travel to the brain, then down to the muscles of the legs and arms to enable the individual to maintain balance and to hold on to a steadying object. While all this activity is going on, the stimulus is relayed through the sympathetic autonomic nerve fibers to the adrenal glands, causing adrenalin to flow, which stimulates heart action. The stimulus then moves to the brain, making the individual conscious of pain. In this example, the spinal cord has functioned not only as a center for spinal reflexes, but also as a conduction pathway for other areas of the spinal cord to the autonomic nervous system and to the brain.

PERIPHERAL NERVOUS SYSTEM

The peripheral nervous system (PNS) consists of the nerves that branch out from the CNS and connect it to the other parts of the body. The PNS includes 12 pairs of cranial nerves and 31 pairs of spinal nerves. Cranial and spinal nerves carry both voluntary and involuntary impulses.

Cranial Nerves

The 12 pairs of cranial nerves are sensory, motor, or mixed (sensory and motor). Table 1-3 shows the 12 cranial nerves and parts of the body they service.

Spinal Nerves

There are 31 pairs of spinal nerves that originate from the spinal cord. Although spinal nerves are not named individually, they are grouped according to the level from which they arise, and each nerve is numbered in sequence. Thus, there are 8 pairs of **cervical** nerves, 12 pairs of **thoracic** nerves, 5 pairs of **lumbar** nerves, 5 pairs of **sacral** nerves, and 1 pair of **coccygeal** nerves. See figure 1-46.

Spinal nerves (mixed) send fibers to sensory surfaces and muscles of the trunk and extremities. Nerve fibers are also sent to involuntary smooth muscles and glands of the gastrointestinal tract, urogenital system, and cardiovascular system.

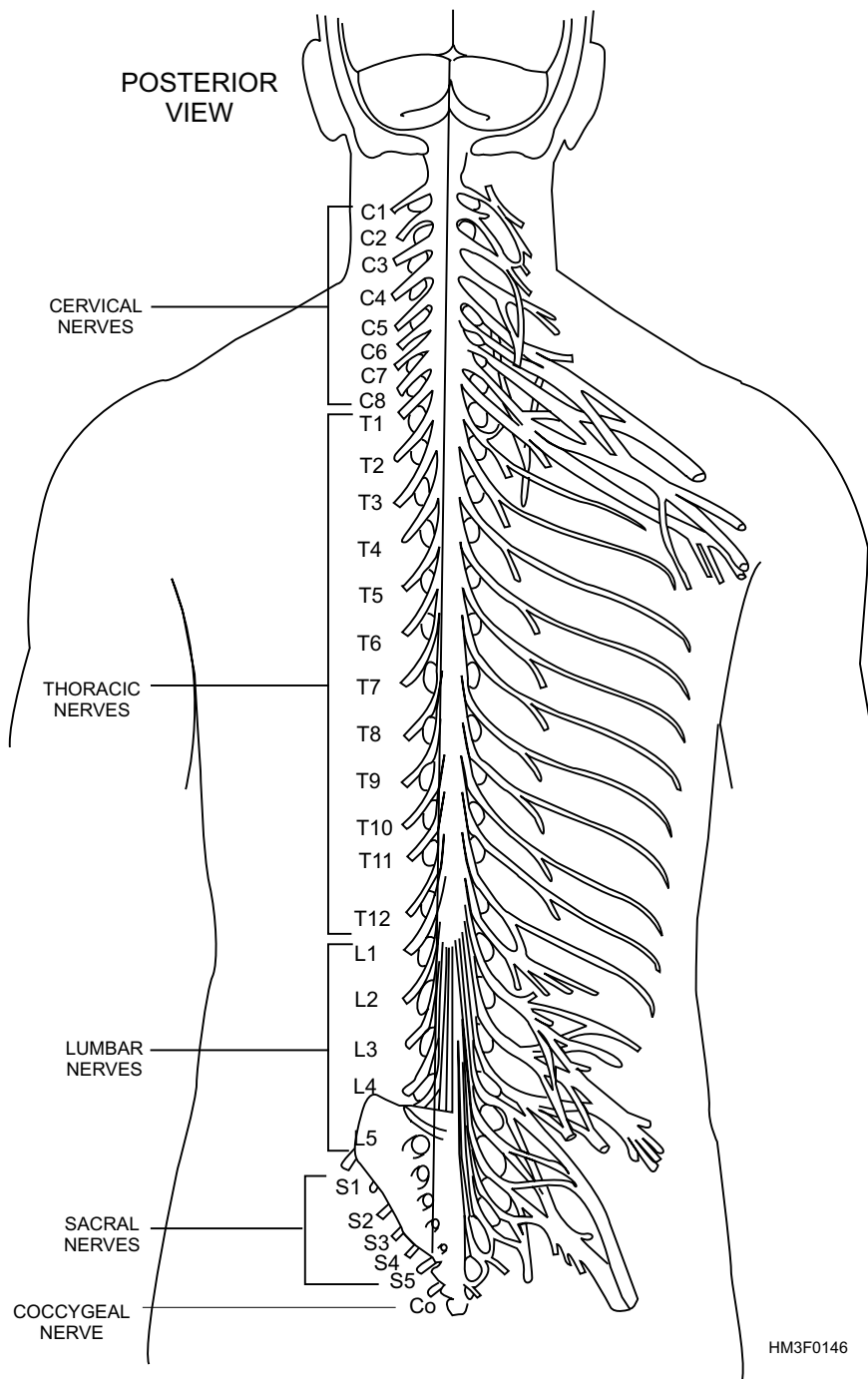


Figure 1-46.—Spinal nerves.

AUTONOMIC NERVOUS SYSTEM

The autonomic nervous system (ANS) is the portion of the PNS that functions independently, automatically, and continuously, without conscious effort. It helps to regulate the smooth muscles, cardiac muscle, digestive tube, blood vessels, sweat and digestive glands, and certain endocrine glands. The autonomic nervous system is not directly under the control of the brain but usually works in harmony with the nerves that are under the brain's control. The

autonomic nervous system includes two subdivisions (the sympathetic and parasympathetic nervous systems) that act together.

The sympathetic nervous system's primary concern is to prepare the body for energy-expending, stressful, or emergency situations. On the other hand, the parasympathetic nervous system is most active under routine, restful situations. The parasympathetic system also counterbalances the effects of the sympathetic system, and restores the body to a resting

Table 1-3.—Cranial Nerves

CRANIAL NERVE	FUNCTION(S)
Olfactory	Sense of smell.
Optic	Vision.
Oculomotor	Eye movement, size of pupil, and eye focus.
Trochlear	Eye movements.
Trigeminal	Sensations of head and face and chewing movements.
Abducens	Abduction of eye (muscles that turn eye outward).
Facial	Facial expressions, secretion of saliva, and sense of taste.
Acoustic	Sense of hearing and balance or equilibrium sense.
Glossopharyngeal	Taste and other sensations of the tongue, swallowing movements, secretion of saliva.
Vagus	Sensations of movement (e.g., decrease in heart rate, increase in peristalsis, and contracting of muscles for voice production).
Accessory	Shoulder movements, turning movements of the head, and voice production.
Hypoglossal	Tongue movements.

state. For example, during an emergency the body's heart and respiration rate increases. After the emergency, the parasympathetic system will decrease heart and respiration rate to normal. The sympathetic and parasympathetic systems counterbalance each other to preserve a harmonious balance of body functions and activities.

THE ENDOCRINE SYSTEM

LEARNING OBJECTIVE: *Identify endocrine glands and the hormone(s) they produce, and determine the effect each hormone has on the body.*

Homeostasis, the self-balancing of the body's internal environment, is achieved and maintained by the endocrine system and the nervous systems. These systems work alone and together to perform similar functions in the body: communication, integration, and control. Their communication capabilities provide the means for controlling and integrating the many different functions performed by organs, tissues, and cells. The endocrine system, however, performs these functions by different mechanisms than the nervous system.

The endocrine system sends messages by way of chemical messengers called **hormones**. Minute amounts of these hormones are secreted from endocrine gland cells into the blood and distributed by the circulatory system. Endocrine glands secrete hormones directly into the blood, because they have no duct system. The glands of this system are often called **ductless glands**. Cells that are affected by the hormone are referred to as **target organ cells**.

Today, many hormones can be extracted from the glands of animals or produced synthetically. Medical officers may prescribe these naturally derived or synthetic hormones for patients who are deficient in them or who might otherwise benefit from their use. For example, oxytocin (the hormone which stimulates uterine contractions during pregnancy) has been synthesized and is used during the delivery process for women who are deficient in this hormone.

The hormone-producing glands include the hypothalamus, pituitary, thyroid, parathyroids, adrenals, pancreas, and gonads (the testes and ovaries) (fig. 1-47).

HYPOTHALAMUS

The hypothalamus, a structure in the brain, synthesizes chemicals that are secreted to the pituitary

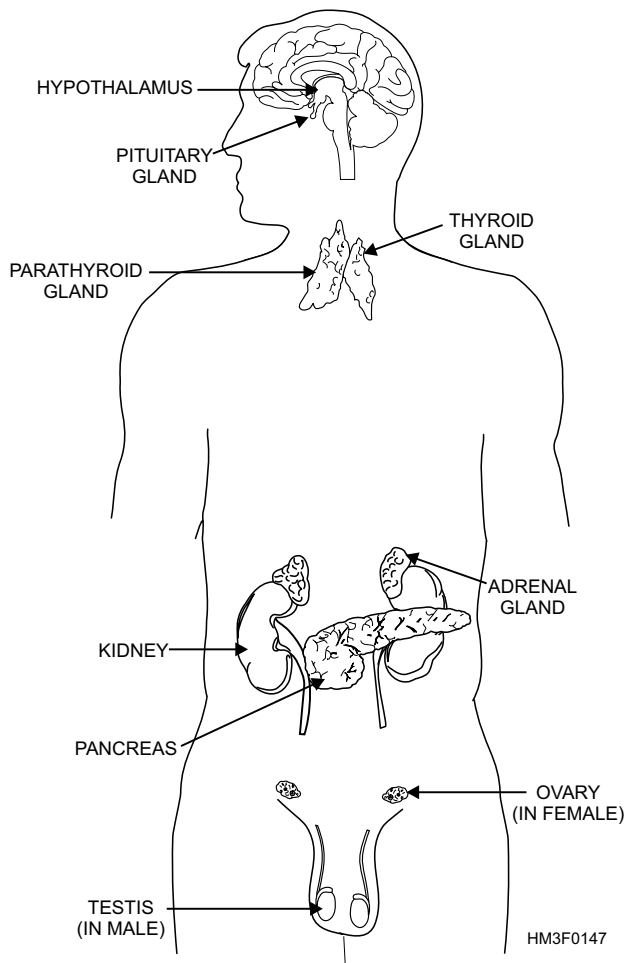


Figure 1-47.—Major endocrine glands.

gland to stimulate the release of its hormones and to help regulate body temperature (fig. 1-47).

PITUITARY GLAND

The pituitary is a small, pea-sized gland located at the base of the brain in the sella turcica, the saddle-shape depression of the sphenoid bone (fig. 1-47). It is often called the master gland of the body because it influences many other endocrine glands. Although the pituitary looks like just one gland, it actually consists of two separate glands, the anterior pituitary gland and the posterior pituitary gland.

Anterior Pituitary Gland

The anterior pituitary gland plays the more important role in influencing body functions. The hormones produced by the anterior pituitary gland have a broad and significant range of effects.

SOMATOTROPIN.—Somatotropin, the growth hormone, influences body growth and development. During the growth years, an overproduction of

somatotropin causes gigantism, while the lack of it causes dwarfism. An overproduction after the growth years causes **acromegaly**, which is characterized by the development of abnormally large hands, feet, and jaw.

THYROTROPIN.—Thyrotropin, or the thyroid-stimulating hormone (TSH), influences the growth, development, and secreting activities of the thyroid gland.

GONADOTROPIN.—Gonadotropin influences the gonads and is essential for the normal development and functioning of both male and female reproductive systems.

ADRENOCORTICOTROPIN.—The adrenocorticotropin hormone (ACTH) acts primarily on the adrenal cortex (the outer portion of the adrenal glands), stimulating its growth and its secretion of corticosteroids. Corticosteroid hormones affect every cell in the body and are discussed in more detail later in this section.

Posterior Pituitary Gland

The posterior pituitary gland produces two hormones, antidiuretic hormone (ADH) and oxytocin.

ANTIDIURETIC.—The ADH hormone, promotes the conservation of water by the kidney. When ADH is not produced in adequate amounts, the daily urine volume is between 10 and 15 liters instead of the normal 1.5 liters. This condition is known as diabetes insipidus.

OXYTOCIN.—Oxytocin stimulates contraction of the muscles of the uterus, particularly during pregnancy. It also plays an important role in the production of milk in the mammary glands of nursing mothers.

THYROID GLAND

The thyroid gland, shaped like a butterfly, lies in the anterior part of the neck, below the larynx (fig. 1-47). It consists of two lobes, one on each side of the upper trachea, connected by a strip of tissue called the isthmus. The thyroid secretes the iodine containing hormone **thyroxin**, which controls the rate of cell metabolism. Excessive secretion of thyroxin raises the metabolic rate and causes hyperthyroidism. This condition is characterized by a fast pulse rate, dizziness, increased basal metabolism, profuse sweating, tremors, nervousness, and a tremendous appetite coupled with a loss of weight.

Iodine is essential for the formation of thyroxin. **Simple goiter**, a diffuse and painless enlargement of the thyroid gland, was once common in areas of the United States where the iodine content of the soil and water was inadequate. In simple goiter, the gland enlarges to compensate for the lack of iodine. To prevent formation of a simple goiter, iodine-containing foods, such as vegetables, iodized salt, and seafood, should be eaten.

A condition known as **hypothyroidism** is caused by an insufficient secretion of thyroxin. The patient exhibits a decrease in basal metabolism, and sweating is almost absent. There may be a weight gain and constant fatigue. The heart rate may be slow, and a simple goiter may form. There may also be personality changes characterized by slow, lethargic mental functioning. Hypothyroidism during childhood can lead to the development of **cretinism**. Cretinism is a condition characterized by retarded mental and physical development.

PARATHYROID GLANDS

Parathyroid glands are four small round bodies located just posterior to the thyroid gland (fig. 1-47). Their hormone, **parathormone** (PTH), regulates the calcium and phosphorus content of the blood and bones. The amount of calcium is important in certain tissue activities, such as bone formation, coagulation of blood, maintenance of normal muscular excitability, and milk production in the nursing mother. Diminished function or removal of the parathyroid glands results in a low calcium level in the blood. In extreme cases death may occur, preceded by strong contraction of the muscles (tetany) and convulsions.

Hyperparathyroidism, an excess of parathyroid hormone in the blood, causes calcium levels in the blood to become elevated by the withdrawal of calcium from the bones, leaving the skeleton demineralized and subject to spontaneous fractures. The excess calcium may be deposited as stones in the kidneys.

ADRENAL GLANDS

The adrenal glands are located on the superior surface of each kidney, fitting like a cap (fig. 1-47). They consist of an outer portion, the cortex, and an inner portion, the medulla.

Adrenal Cortex

Specialized cells in the outer layer of the adrenal cortex produce three types of steroid hormones that are of vital importance.

MINERALOCORTICIDS.—Mineralocorticoids are regulators of fluid and electrolyte balance. They are sometimes called salt and water hormones because they regulate the excretion and absorption of sodium, chlorine, potassium, and water.

GLUCOCORTICIDS.—Glucocorticoids are essential to metabolism. They increase certain liver functions and have an anti-inflammatory effect. Clinically, they are used to suppress inflammatory reactions, to promote healing, and to treat rheumatoid arthritis.

ANDROGENS AND ESTROGENS.—The adrenal cortex also produces sex hormones, some with male characteristics (**androgens**), others with female characteristics (**estrogens**). These hormones appear in different concentrations in both men and women.

Adrenal Medulla

The adrenal medulla secretes **epinephrine** (**adrenalin**) in the presence of emotional crises, hypoglycemia (low blood sugar), or low blood pressure. Epinephrine causes powerful contractions of many arterioles (especially in the skin, mucous membranes, and kidneys), but it dilates other arterioles (such as those of the coronary system, skeletal muscles, and lungs). Heart rate, respiration rate and depth, blood pressure, blood sugar levels, and metabolism are all increased by epinephrine. It also stimulates the production of other adrenal cortical hormones.

Norepinephrine is also produced in the adrenal medulla. It is a chemical precursor to epinephrine. Its effects are similar to those of epinephrine, but its action differs.

Despite these marked influences, the medullary tissue of the adrenal gland is not essential to life, because its various functions can be assumed by other regulatory mechanisms.

PANCREAS

The pancreas contains two types of secretory tissues. The first secretory tissue secretes digestive juice through a duct to the small intestine, while the other tissue releases hormones into body fluids. The

endocrine portion of the pancreas consists of cells arranged in groups, called “**islands (islets) of Langerhans.**” The islands (islets) of Langerhans contain three types of endocrine cells: alpha, beta, and delta. The **alpha cells** secrete the hormone glucagon. **Glucagon** causes a temporary rise in blood sugar levels. The **beta cells** secrete insulin, which is essential for carbohydrate metabolism. **Insulin** lowers blood sugar levels by increasing tissue utilization of glucose and stimulating the formation and storage of glycogen in the liver. Together, glucagon and insulin act to regulate sugar metabolism in the body. **Delta cells** produce the hormone **somatostatin**. Somatostatin helps regulate carbohydrates by inhibiting the secretion of glucagon.

When the islet cells are destroyed or stop functioning, the sugar absorbed from the intestine remains in the blood and excess sugar is excreted by the kidneys into the urine. This condition is called **diabetes mellitus**, or sugar diabetes. Insulin, a synthetic hormone, is given to patients having this disease as part of their ongoing treatment.

GONADS (TESTES AND OVARIES)

The term **gonads** refers to the primary sex organs of the reproductive system (male and female).

Testes

The male gonad is the testis (*pl.* testes), and the existence of the testes is the primary male sex characteristic (fig. 1-47). The testes produce and secrete the male hormone **testosterone**, which influences the development and maintenance of the male accessory sex organs and the secondary sex characteristics of the male. The male **accessory sex organs** include two groups of organs: the internal sex organs and the external sex organs. See section titled “Male Reproductive System” for more information on the male accessory sex organs.

Male Secondary Sex Characteristics

Male secondary sex characteristics influenced by the hormone testosterone are as follows:

- Increased growth of hair, particularly in the areas of the face, chest, axilla, and pubic region.

- Enlargement of the larynx (Adam's apple) and thickening of the vocal cords, which produces a lower-pitched voice.
- Thickening of the skin.
- Increased muscle growth, broadening of the shoulder and narrowing of the waist.
- Thickening and strengthening of the bones.

Ovaries

The female gonads, the ovaries, produce the hormones **estrogen** and **progesterone** (fig. 1-47). Estrogen influences the development and maintenance of the female accessory sex organs and the secondary sex characteristics, and promotes changes in the mucous lining of the uterus (endometrium) during the menstrual cycle. Progesterone prepares the uterus for the reception and development of the fertilized ovum and maintains the lining during pregnancy.

Today, progesterone and estrogen hormones (naturally derived) are incorporated into oral contraceptives or birth control pills. The combination of hormones released through this monthly series of pills fools the body into not preparing (building-up of uterine lining) for implantation of an embryo. Because the uterus has not prepared for implantation, pregnancy cannot occur.

Female accessory sex organs are also divided into internal and external accessory sex organs. See section titled “Female Reproductive System” for more information on the female accessory sex organs.

Female Secondary Sex Characteristics

Female secondary sex characteristics influenced by the hormone estrogen are listed below.

- Development of the breasts and the ductile system of the mammary glands within the breasts.
- Increased quantities of fatty (or adipose) tissue in the subcutaneous layer, especially in the breasts, thighs, and buttocks.
- Increased vascularization of the skin.

THE SENSORY SYSTEM

LEARNING OBJECTIVE: *Recognize the senses of the body, and identify their physical characteristics.*

The sensory system informs areas of the cerebral cortex of changes that are taking place within the body or in the external environment. The special sensory receptors respond to special individual stimuli such as sound waves, light, taste, smell, pressure, heat, cold, pain, or touch. Positional changes, balance, hunger, and thirst sensations are also detected and passed on to the brain.

SMELL

Odor is perceived upon stimulation of the receptor cells in the **olfactory** membrane of the nose. The olfactory receptors are very sensitive, but they are easily fatigued. This tendency explains why odors that are initially very noticeable are not sensed after a short time. Smell is not as well developed in man as it is in other mammals.

TASTE

The taste buds are located in the tongue. The sensation of taste is limited to **sour, sweet, bitter, and salty**. Many foods and drinks tasted are actually smelled, and their taste depends upon their odor. (This interdependence between taste and smell can be demonstrated by pinching the nose shut when eating onions.) Sight can also affect taste. Several drops of green food coloring in a glass of milk will make it all but unpalatable, even though the true taste has not been affected.

SIGHT

The eye, the organ of sight, is a specialized structure for the reception of light. It is assisted in its function by accessory structures, such as the eye brows, eyelashes, eyelids, and **lacrimal apparatus**. The lacrimal apparatus consists of structures that produce tears and drains them from the surface of the eyeball.

Structure of the Eye

Approximately five-sixths of the eyeball lies recessed in the orbit, protected by a bony socket. Only the small anterior surface of the eyeball is exposed.

The eye is not a solid sphere but contains a large interior cavity that is divided into two cavities, anterior and posterior. The anterior cavity is further subdivided into anterior and posterior chambers (fig. 1-48).

The **anterior cavity** of the eye lies in front of the lens. The **anterior chamber** of the anterior cavity is the space anterior to the iris, but posterior to the cornea. The **posterior chamber** of the anterior cavity consists of a small space directly posterior to the iris, but anterior to the lens. Both chambers of the anterior cavity are filled with a clear, watery fluid called **aqueous humor**. Aqueous humor helps to give the cornea its curved shape.

The **posterior cavity** of the eye is larger than the anterior cavity, since it occupies all the space posterior to the lens, suspensory ligaments, and ciliary body. The posterior cavity contains a substance, with the consistency similar to soft gelatin, called **vitreous humor**. Vitreous humor helps maintain sufficient pressure inside the eye to prevent the eyeball from collapsing.

The eyeball is composed of three layers. From the outside in, they are the sclera, choroid, and retina (fig. 1-48).

OUTER LAYER.—The outer layer of the eye is called the **sclera**. The sclera is the tough, fibrous, protective portion of the globe, commonly called the white of the eye. Anteriorly, the outer layer is transparent and is called the **cornea**, or the window of the eye. It permits light to enter the globe. The exposed sclera is covered with a mucous membrane, the conjunctiva, which is a continuation of the inner lining of the eyelids. The **lacrimal gland** produces tears that constantly wash the front part of the eye and the conjunctiva. The tear gland secretions that do not

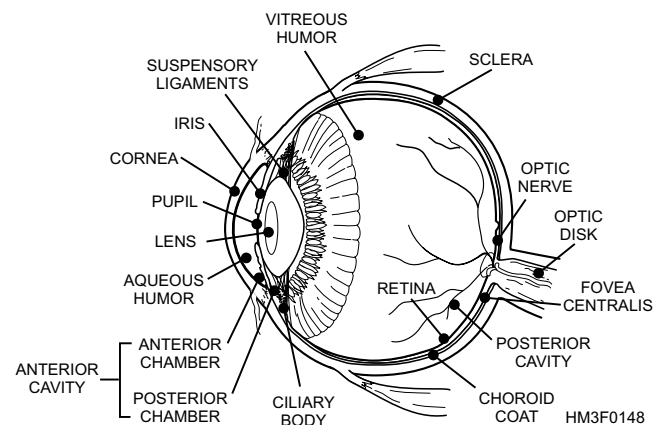


Figure 1-48.—Transverse section of the eye.

evaporate flow toward the inner angle of the eye, where they drain down ducts into the nose.

MIDDLE LAYER.—The middle layer of the eye is called the **choroid**. This layer is a highly vascular, pigmented tissue that provides nourishment to the inner structures. Continuous with the choroid is the **ciliary body**. The ciliary body is formed by a thickening of the choroid and fits like a collar into the area between the retina and iris. Attached to the ciliary body are the **suspensory ligaments**, which blend with the elastic capsule of the lens and holds it in place.

Iris.—The iris is continuous with the ciliary body. The iris is a circular, pigmented muscular structure that gives color to the eye. The iris separates the anterior cavity into anterior and posterior chambers. The opening in the iris is called the **pupil** (fig. 1-49). The amount of light entering the pupil is regulated through the constriction of radial and circular muscles in the iris. When strong light is flashed into the eye, the circular muscle fibers of the iris contract, reducing the size of the pupil. If the light is dim, the pupil dilates to allow as much of the light in as possible. The size and

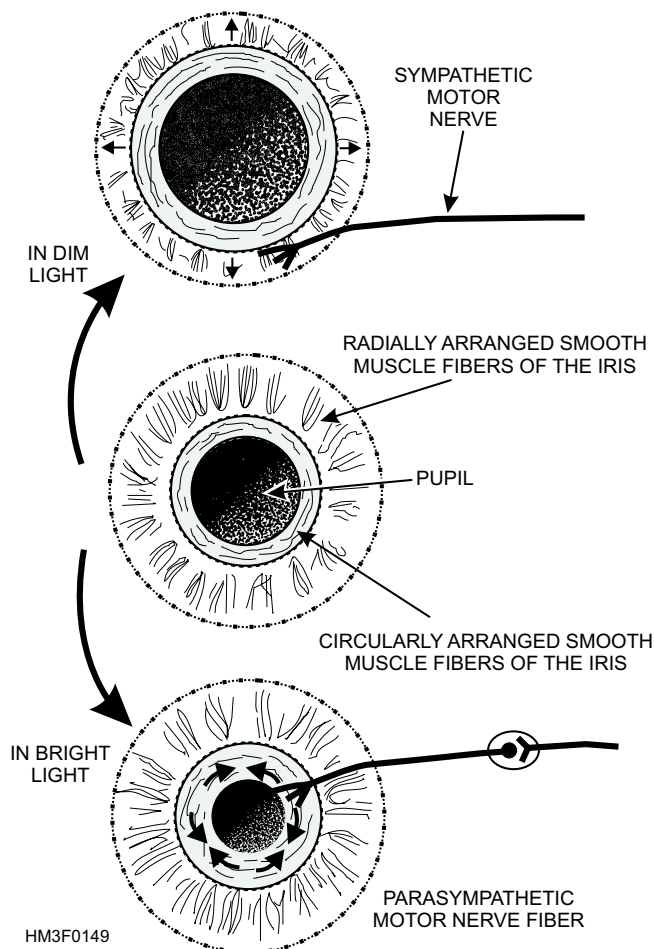


Figure 1-49.—Anterior view of the eye.

reaction of the pupils of the eyes are an important diagnostic tool.

Lens.—The lens is a transparent, biconvex (having two convex surfaces) structure suspended directly behind the iris. The optic globe posterior to the lens is filled with a jellylike substance called vitreous humor, which helps to maintain the shape of the eyeball by maintaining intraocular pressure. The lens separates the eye into anterior and posterior cavities.

INNER LAYER.—The inner layer of the eye is called the **retina** (fig. 1-48). It contains layers of the nerve cells, **rods**, and **cones** that are the receptors of the sense of vision. The retina is continuous with the **optic nerve**, which enters the back of the globe and carries visual impulses received by the rods and cones to the brain. The area where the optic nerve enters the eyeball contains no rods and cones and is called the **optic disc** (blind spot) (fig. 1-50).

Rods.—Rods respond to low intensities of light and are responsible for night vision. They are located in all areas of the retina, except in the small depression called the **fovea centralis**, where light entering the eye is focused, and which has the clearest vision.

Cones.—Cones require higher light intensities for stimulation and are most densely concentrated in the fovea centralis. The cones are responsible for daytime vision.

Vision Process

The vision process begins with rays of light from an object passing through the cornea. The image is then received by the lens, by way of the iris. Leaving the lens, the image falls on the rods and cones in the retina. The image then is carried to the brain for interpretation by the optic nerve (fig. 1-51). Note the image received by the retina is upside down, but the brain turns it right-side up.

REFRACTION.—Deflection or bending of light rays results when light passes through substances of varying densities in the eye (cornea, aqueous humor, lens, and vitreous humor). The deflection of light in the eye is referred to as **refraction**.

ACCOMMODATION.—Accommodation is the process by which the lens increases or decreases its curvature to refract light rays into focus on the fovea centralis.

CONVERGENCE.—The movement of the globes toward the midline, causes a viewed object to come into focus on corresponding points of the two

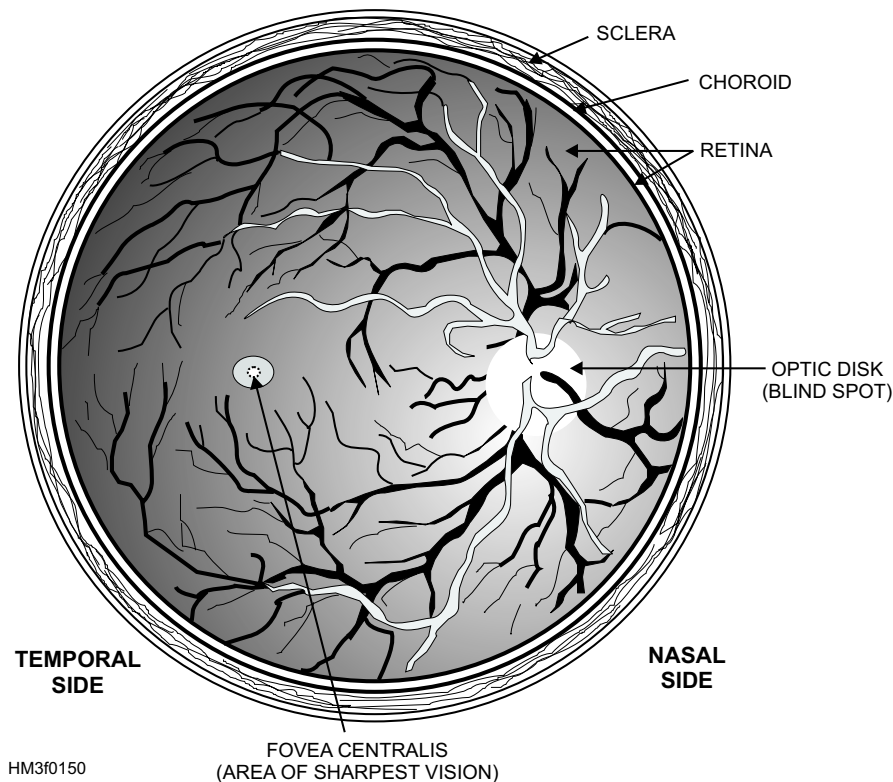


Figure 1-50.—Ophthalmoscope view of the eye.

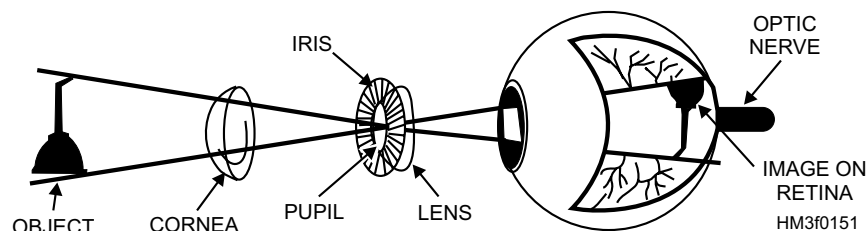


Figure 1-51.—The vision process.

retinas. This process, called **convergence**, produces clear, three-dimensional vision.

HEARING

The ear is the primary organ of hearing. Its major parts are illustrated in figure 1-52. The ear is divided into three parts: the external, middle, and inner ear.

External Ear

The external (outer) ear is composed of two parts, the **auricle** and the **external auditory canal** (fig. 1-52). The auricle, or pinna, is a cartilaginous structure located on each side of the head. The auricle collects sound waves from the environment, which are then conducted by the external auditory canal to the eardrum. The lining of the external auditory canal contains glands that secrete a wax-like substance

called **cerumen**. Cerumen aids in protecting the eardrum against foreign bodies and microorganisms.

The **tympanic membrane**, or eardrum, is an oval sheet of fibrous epithelial tissue that stretches across the inner end of the external auditory canal. The eardrum separates the outer and middle ear. The sound waves cause the eardrum to vibrate, and this vibration transfers the sounds from the external environment to the auditory ossicles.

Middle Ear

The middle ear is a cavity in the temporal bone, lined with epithelium. It contains three **auditory ossicles**—the malleus (hammer), the incus (anvil), and the stapes (stirrup)—which transmit vibrations from the tympanic membrane to the fluid in the inner ear

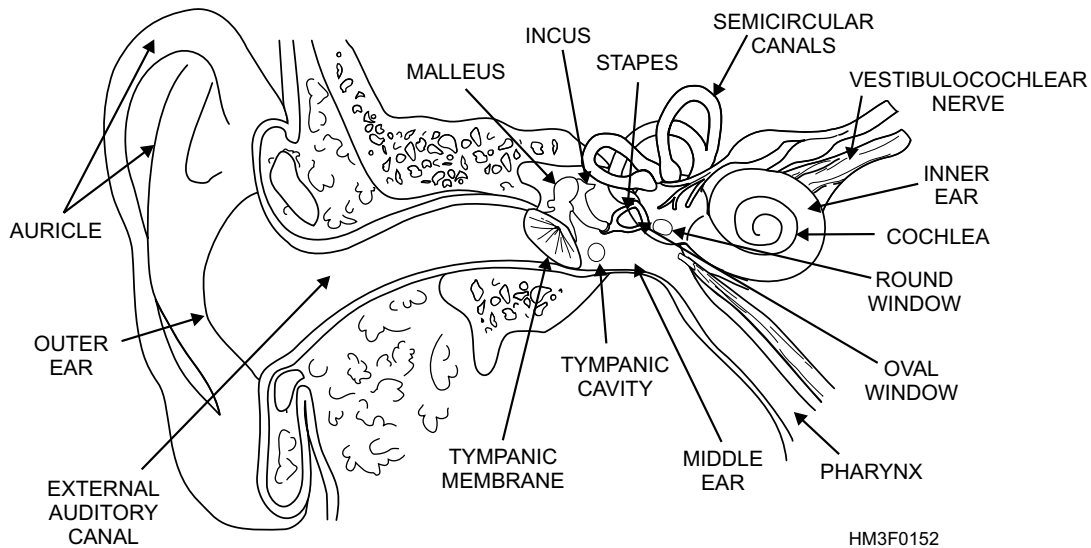


Figure 1-52.—Major parts of the ear.

(fig. 1-52). The **malleus** is attached to the inner surface of the eardrum and connects with the **incus**, which in turn connects with the **stapes**. The base of the stapes is attached to the **fenestra ovalis** (oval window), the membrane-covered opening of the inner ear. These tiny bones, which span the middle ear, are suspended from bony walls by ligaments. This arrangement provides the mechanical means for transmitting sound vibrations to the inner ear.

The **eustachian tube**, or auditory tube, connects the middle ear with the pharynx. It is lined with a mucous membrane and is about 36 mm long. Its function is to equalize internal and external air pressure. For example, while riding an elevator in a tall building, you may experience a feeling of pressure in the ear. This condition is usually relieved by swallowing, which opens the eustachian tube and allows the pressurized air to escape and equalize with the area of lower pressure. Divers who ascend too fast to allow pressure to adjust may experience rupture of their eardrums. The eustachian tube can also provide a pathway for infection of the middle ear.

Inner Ear

The inner ear is filled with a fluid called **endolymph**. Sound vibrations that cause the stapes to move against the oval window create internal ripples that run through the endolymph. These pressurized ripples move to the **cochlea**, a small snail-shaped structure housing the **organ of Corti**, the hearing organ (fig. 1-52). The cells protruding from the organ of Corti are stimulated by the ripples to convert these mechanical vibrations into nerve impulses, and these

impulses are relayed through the vestibulocochlear (8th cranial) nerve to the auditory area of the cortex in the temporal lobe of the brain. There they are interpreted as the sounds we hear.

Another structure located in the inner ear is composed of the **three semicircular canals**, situated perpendicular to each other. Movement of the endolymph within the canals, caused by general body movements, stimulates nerve endings, which report these changes in body position to the brain, which in turn uses the information to maintain equilibrium.

The **fenestra rotunda** (round window) is another membrane-covered opening of the inner ear. It contracts the middle ear and flexes to accommodate the inner ear ripples caused by the stapes.

TOUCH

Until the beginning of the last century, touch (feeling) was treated as a single sense. Thus, warmth or coldness, pressure, and pain, were thought to be part of a single sense of touch or feeling. It was discovered that different types of nerve ending **receptors** are widely and unevenly distributed in the skin and mucous membranes. For example, the skin of the back possesses relatively few touch and pressure receptors while the fingertips have many. The skin of the face has relatively few cold receptors, and mucous membranes have few heat receptors. The cornea of the eye is sensitive to pain, and when pain sensation is abolished by a local anesthetic, a sensation of touch can be experienced.

Receptors are considered to be sensory organs. They provide the body with the general senses of touch, temperature, and pain. In addition, these receptors initiate reactions or reflexes in the body to maintain homeostasis. For example, receptors in the skin perceive cold, resulting in goosebumps. This reaction is the body's attempt to maintain internal warmth.

Receptors are classified according to location, structure, and types of stimuli activating them. Classified according to location, the three types of receptors are as follows: **superficial receptors** (exteroceptors), **deep receptors** (proprioceptors), and **internal receptors** (visceroceptors). See table 1-4 for receptor locations and the senses resulting from the stimulation of these receptors.

THE DIGESTIVE SYSTEM

LEARNING OBJECTIVE: *Identify the location and function of each part of the digestive system.*

The digestive system includes the organs that digest and absorb food substances, and eliminate the unused residuals. The digestive system consists of the **alimentary canal** and several accessory organs. The accessory organs release secretions into the canal. These secretions assist in preparing food for absorption and use by the tissues of the body. Table 1-5 illustrates principal digestive juices (secretions) produced by alimentary and accessory organs.

Digestion is both mechanical and chemical. Mechanical digestion occurs when food is chewed, swallowed, and propelled by a wave-like motion called **peristalsis**. When peristalsis occurs, a ring of

contraction appears in the walls of the alimentary canal. At the same time, the muscular wall just ahead of the ring relaxes. This phenomenon is called **receptive relaxation**. As the wave moves along, it pushes the canal's contents ahead of it. Chemical digestion consists of changing the various food substances, with the aid of digestive enzymes, into solutions and simple compounds. Carbohydrates (starches and sugars) change into simple sugars (glucose); fats change into fatty acids; and proteins change into amino acids. Once the food substances have been broken down into simple compounds, the cells of the body can absorb and use them.

THE ALIMENTARY CANAL

The alimentary canal (tract) is 9 meters in length, tubular, and includes the mouth, pharynx, esophagus, stomach, small intestine, and large intestine (fig. 1-53).

Mouth

The mouth, which is the first portion of the alimentary canal, is adapted to receive food and prepare it for digestion (fig. 1-53). The mouth mechanically reduces the size of solid particles and mixes them with saliva. This process is called **mastication**. Saliva, produced by the **salivary gland**, moistens food making it easier to chew. Saliva also lubricates the food mass to aid swallowing. The tongue assists with both mastication and swallowing.

Pharynx

The pharynx (covered earlier in “The Respiratory System”) is the passageway between the mouth and the esophagus and is shared with the respiratory tract (fig. 1-53). The **epiglottis** is a cartilaginous flap that

Table 1-4.—Types of Receptors, Their Location, and Affected Sense

TYPES	LOCATIONS	SENSES
Superficial receptors	At or near surface of body	Touch, pressure, heat, cold, and pain
Deep receptors	In muscles, tendons, and joints	Sense of position and movement
Internal receptors	In the internal organs and blood vessel walls	Usually none (except hunger, nausea, pain from stimuli such as chemicals (e.g., aspirin) and distension (e.g., stomach expansion from gas))

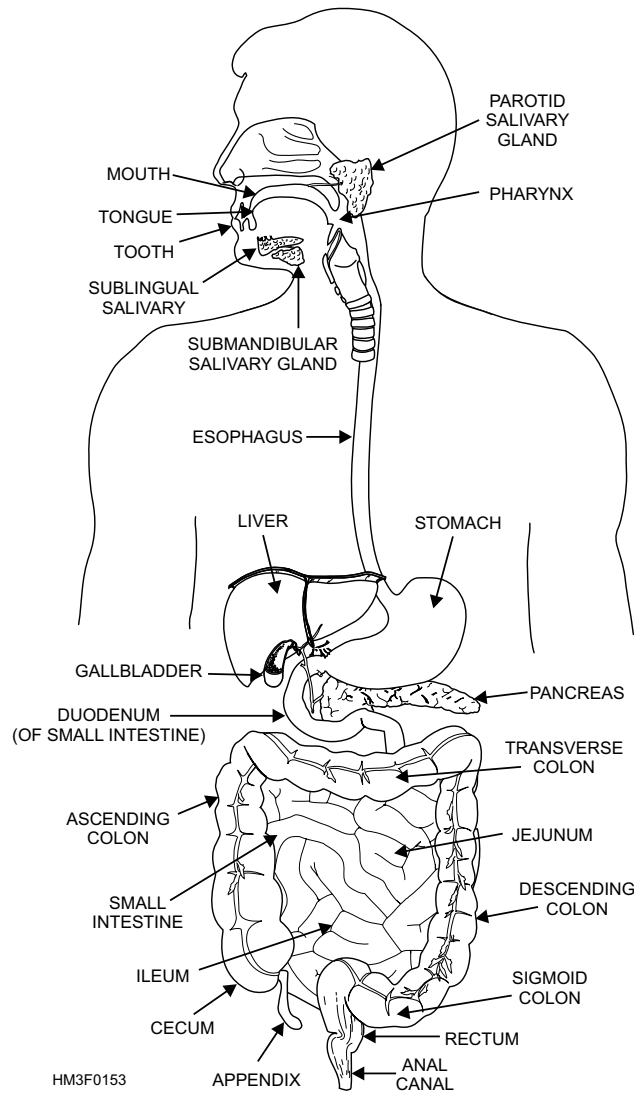


Figure 1-53.—The digestive system.

Table 1-5.—Principal Digestive Juices

Digestive Juice	Source	Substance Acted Upon	Product
Amylase	Salivary glands and pancreas	Starch	Complex sugars (maltose)
Hydrochloric acid	Gastric glands	Pepsinogen (Proteins)	Pepsin (Split proteins)
Bile	Liver	Fats	Emulsified fats
Proteinase	Pancreas	Proteins and split proteins	Peptides and polypeptides
Lipase	Pancreas	Fats (triglycerides)	Fatty acids and glycerol
Carbohydrase	Intestinal glands	Complex sugars (maltose, sucrose, and lactose)	Simple sugars (glucose, fructose, and galactose)
Peptidase	Intestinal glands	Peptides and polypeptides	Amino acids

closes the opening to the larynx when food is being swallowed down the pharynx. Food is deflected away from the trachea to prevent particle aspiration (inhalation).

Esophagus

The esophagus is a muscular tube about 25 cm (10 inches) long (fig. 1-53). It is the passageway between the pharynx and the stomach. By means of peristalsis, food is pushed along this tube to the stomach. When peristalsis is reversed, vomiting occurs.

Stomach

The stomach acts as an initial storehouse for swallowed material and helps in the chemical breakdown of food substances. The stomach is a saccular enlargement of the gastrointestinal tube and lies in the left upper quadrant of the abdomen (fig. 1-53). It connects the lower end of the esophagus with the first portion of the small intestine (the duodenum). The stomach is divided into the **cardiac**, **fundic**, **body**, and **pyloric** regions (fig. 1-54). At each end of the stomach, muscular rings (or sphincters) form valves to close off the stomach. The sphincters prevent the stomach's contents from escaping in either direction while food substances are being mixed by peristaltic muscular contractions of the stomach wall. The sphincter at the esophageal end is the **cardiac sphincter**; at the duodenal end it is the **pyloric sphincter**.

The chemical breakdown of food in the stomach is accomplished through the production of digestive juices (**enzymes**) by small (**gastric**) glands in the wall of the stomach. The principal digestive enzymes produced by the gastric glands are **hydrochloric acid** and **pepsinogen**. Hydrochloric acid activates pepsin from pepsinogen, kills bacteria that enter the stomach, inhibits the digestive action of amylase, and helps regulate the opening and closing of the pyloric sphincter. **Pepsin** is a protein-splitting enzyme capable of beginning the digestion of nearly all types of dietary protein.

Most food absorption takes place in the small intestine. In general, food is not absorbed in the stomach. An exception is alcohol, which is absorbed directly through the stomach wall. It is for this reason that intoxication occurs quickly when alcohol is taken on an empty stomach.

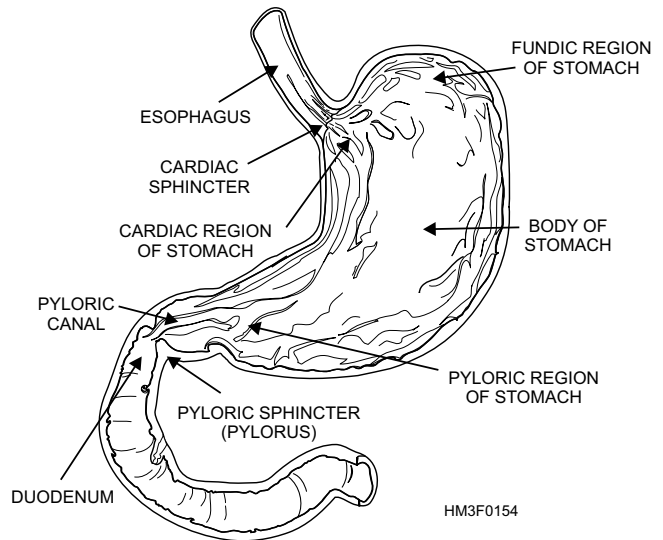


Figure 1-54.—Major regions of the stomach.

Abdominal Cavity

The stomach and intestines are enclosed in the abdominal cavity, the space between the diaphragm and the pelvis. This cavity is lined with serous membrane called the **peritoneum**. The peritoneum covers the intestines and the organs and, by secreting a serous fluid, prevents friction between adjacent organs. The **mesentery** (double folds of peritoneum) extends from the cavity walls to the organs of the abdominal cavity, suspending them in position and carrying blood vessels to the organs.

Small Intestine

The small intestine is a muscular, convoluted, coiled tube, about 7 meters (23 feet) long and attached to the posterior abdominal wall by its mesentery (fig. 1-53).

The small intestine is divided into three contiguous parts: the duodenum, jejunum, and ileum. It receives digestive juices from three accessory organs of digestion: the pancreas, liver, and gallbladder.

DUODENUM.—The duodenum is approximately 25 cm (10 inches) long and forms a C-shaped curve around the head of the pancreas, posterior to the liver. It is lined with a mucous membrane that contains small glands. These glands secrete intestinal juices containing the enzymes carbohydrase, peptidase, and lipase.

JEJUNUM.—The jejunum is the middle part of the small intestine and is approximately 2.5 meters (8.2 feet) long. Its enzymes continue the digestive process.

ILEUM.—The ileum is the last and longest part of the small intestine. It is approximately 3.5 meters (11.5 feet) long. Most of the absorption of food occurs in the ileum, where fingerlike projections (**villi**) provide a large absorption surface. After ingestion, it takes 20 minutes to 2 hours for the first portion of the food to pass through the small intestine to the beginning of the large intestine.

Large Intestine

The large intestine is so called because it is larger in diameter than the small intestine (fig. 1-53). It is considerably shorter, however, being about 1.5 meters (5 feet) long. It is divided into three distinct parts: the cecum, colon, and rectum.

CECUM AND COLON.—The unabsorbed food or waste material passes through the **cecum** into the **ascending colon**, across the **transverse colon**, and down the **descending colon** through the **sigmoid colon** to the rectum. Twelve hours after the meal, the waste material passes slowly through the colon, building in mass and reaching the rectum 24 hours after the food is ingested.

The **appendix**, a long narrow tube with a blind end, is a pouchlike structure of the cecum located near the junction of the ileum and the cecum (fig. 1-53). There is no known function of this structure. Occasionally, the appendix becomes infected, causing inflammation to develop. This inflammation of the appendix is known as **appendicitis**.

RECTUM.—The rectum is approximately 12.5 cm (5 inches) long and follows the contour of the sacrum and coccyx until it curves back into the short (2.5 to 4 cm) anal canal. The **anus** is the external opening at the lower end of the digestive system. Except during bowel movement (defecation), it is kept closed by a strong muscular ring, the **anal sphincter**.

ACCESSORY ORGANS OF DIGESTION

The accessory organs of digestion include the salivary glands, pancreas, liver, and gallbladder. As stated earlier, during the digestive process, the accessory organs produce secretions that assist the organs of the alimentary canal.

Salivary Glands

The salivary glands are located in the mouth (fig. 1-53). Within the salivary glands are two types of secretory cells, serous cells and mucous cells. The

serous cells produce a watery fluid that contains a digestive juice called **amylase**. Amylase splits starch and glycerol into complex sugars. The mucous cells secrete a thick, sticky liquid called **mucus**. Mucus binds food particles together and acts to lubricate during swallowing. The fluids produced by the serous and mucous cells combine to form **saliva**. Approximately 1 liter of saliva is secreted daily.

Pancreas

The pancreas is a large, elongated gland lying posteriorly to the stomach (fig. 1-53). As discussed earlier in “The Endocrine System,” the pancreas has two functions: It serves both the endocrine system and the digestive system. The digestive portion of the pancreas produces digestive juices (amylase, proteinase, and lipase) that are secreted through the pancreatic duct to the duodenum. These digestive juices break down carbohydrates (amylase), proteins (proteinase), and fats (lipase) into simpler compounds.

Liver

The liver is the largest gland in the body. It is located in the upper abdomen on the right side, just under the diaphragm and superior to the duodenum and pylorus (fig. 1-53).

Of the liver's many functions, the following are important to remember:

- It metabolizes carbohydrates, fats, and proteins preparatory to their use or excretion.
- It forms and excretes bile salts and pigment from bilirubin, a waste product of red blood cell destruction.
- It stores blood; glycogen; vitamins A, D, and B₁₂; and iron.
- It detoxifies the end products of protein digestion and drugs.
- It produces antibodies and essential elements of the blood-clotting mechanism.

Gallbladder

The gallbladder is a pear-shaped sac, usually stained dark green by the bile it contains. It is located in the hollow underside of the liver (fig. 1-53). Its duct, the **cystic duct**, joins the **hepatic duct** from the liver to form the **common bile duct**, which enters the duodenum. The gallbladder receives bile from the liver and then concentrates and stores it. It secretes bile

when the small intestine is stimulated by the entrance of fats.

THE URINARY SYSTEM

LEARNING OBJECTIVE: *Recall the parts of the urinary system and their function(s).*

The urinary system is the primary filtering system of the body (fig. 1-55). This system is composed of two main organs, the **kidneys** and **urinary bladder**. The kidneys produce urine, which is drained from the kidneys by two tubes called **ureters**. Urine flows down both ureters to the bladder. The urinary bladder is a large reservoir where the urine is temporarily stored before excretion from the body. A tube called the **urethra** carries the urine from the bladder to the outside of the body. All these parts, except the length of the urethra, are the same in both sexes.

KIDNEYS

The importance of the kidney can be realized only when its structure and functions are understood. The bladder, ureters, and urethra store and pass the products of the kidneys.

The kidneys are two large, bean-shaped organs designed to filter waste materials from the blood (figs. 1-55 and 1-56). They also assist in controlling the rate of red blood cell formation, and in the regulation of blood pressure, the absorption of calcium ions, and the

volume, composition, and pH of body fluids. The kidneys are located in the upper posterior part of the abdominal cavity, one on each side of the spinal column. The upper end of each kidney reaches above the level of the 12th rib. The suprarenal (adrenal) gland sits like a cap on top of each kidney. The kidneys are protected by a considerable amount of fat and supported by connective tissue and the peritoneum. Attached to the hollow side of each kidney is the dilated upper end of the ureter, forming the **renal pelvis**.

Structure

The lateral surface of the kidneys is convex in shape, and the medial side is deeply concave. The medial side of each kidney possesses a depression that leads to a hollow chamber called the **renal sinus** (fig. 1-55). The entrance of the renal sinus is referred to as the **hilum** (fig. 1-55). Blood vessels, nerves, lymphatic vessels, and the ureters pass through the hilum.

The superior end of the ureter forms a funnel-shaped sac called the **renal pelvis** (fig. 1-56). The renal pelvis is divided into two or three tubes, called **major calyces**. The major calyces (*sing.* calyx) are further subdivided into **minor calyces**.

There are groups of elevated projections in the walls of the renal pelvis. These projections are called **renal papillae**. The renal papillae connect to the minor calyces, through tiny openings in the minor calyces.

The principal portion of the kidney is divided into two distinct regions: an inner medulla and outer cortex (fig. 1-56). The **renal medulla** is composed of pyramid-shaped masses of tubes and tubules called **renal pyramids**. **Renal pyramids** drain the urine to the renal pelvis. The **renal cortex** forms a shell over the renal medulla. Renal cortex tissue dips down, like fingers, between the renal pyramids, and forms what are called **renal columns**. The cortex possesses very small tubes associated with **nephrons**. Nephrons are the functional units of the kidneys.

RENAL BLOOD VESSELS.—The **renal artery** supplies blood to the kidneys (fig. 1-56). The renal artery enters the kidneys through the hilum, and sends off branches to the renal pyramids. These arterial branches are called **interlobar arteries**. At the border between the medulla and cortex, the interlobar arteries branch to form the **arciform arteries**. The arciform arteries branch also and form the **interlobular arteries**.

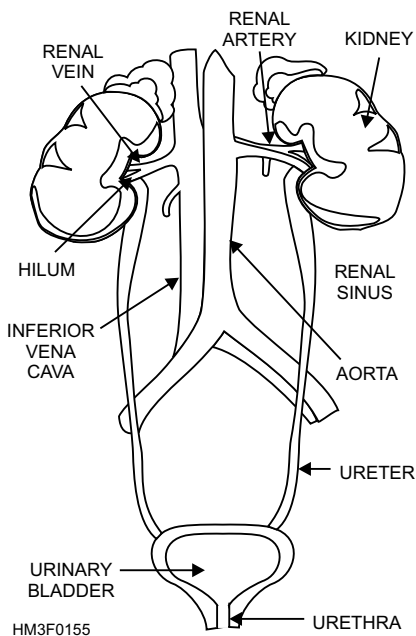


Figure 1-55.—The urinary system.

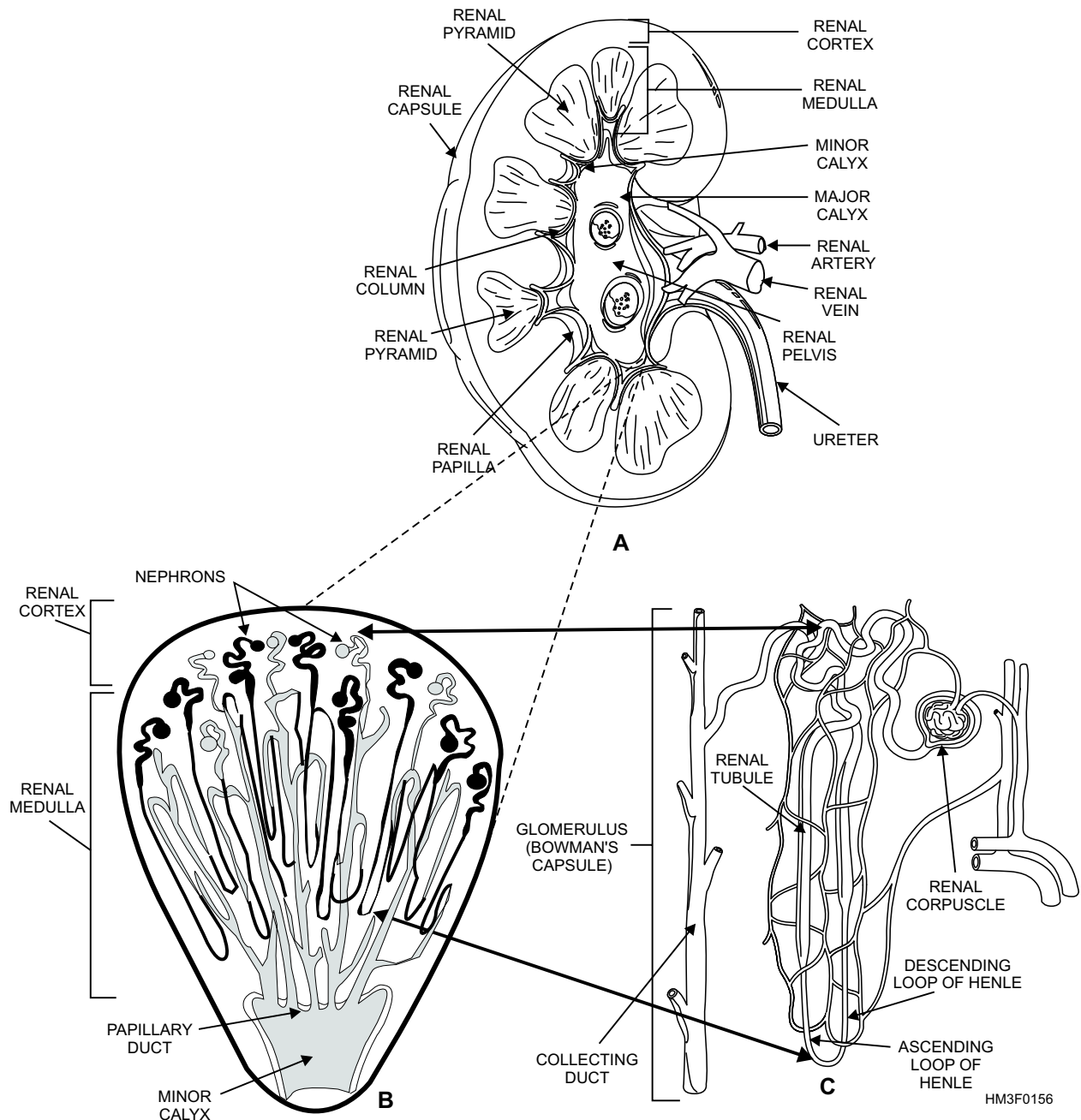


Figure 1-56.—Principal parts of the kidney: A. Longitudinal section of a kidney; B. A renal pyramid containing nephrons; C. A single nephron.

The venous system of the kidneys generally follow the same paths as the arteries. Venous blood passes through the interlobular, arciform, interlobar, and renal veins (fig. 1-56).

NEPHRONS.—The functional units of the kidneys are called nephrons. There are about 1 million nephrons in each kidney. Each nephron consists of a renal corpuscle and a renal tubule (fig. 1-56, view C).

The **renal corpuscle** (**Malpighian corpuscle**) is composed of a tangled cluster of blood capillaries called a **glomerulus**. The glomerulus is surrounded by a sac-like structure referred to as the **glomerulus**

capsule or **Bowman's capsule** (figs. 1-56, view C, and 1-57).

Leading away from the glomerulus is the renal tubule. The initial portion of the renal tubule is coiled and called the **proximal convoluted** (meaning coiled or twisted) **tubule**. The proximal convoluted tubule dips down to become the **descending loop of Henle**. The tubule then curves upward toward the renal corpuscle and forms the **ascending loop of Henle**.

Once the ascending limb reaches the region of the renal corpuscle, it called the **distal convoluted tubule**. Several distal convoluted tubules merge in the renal

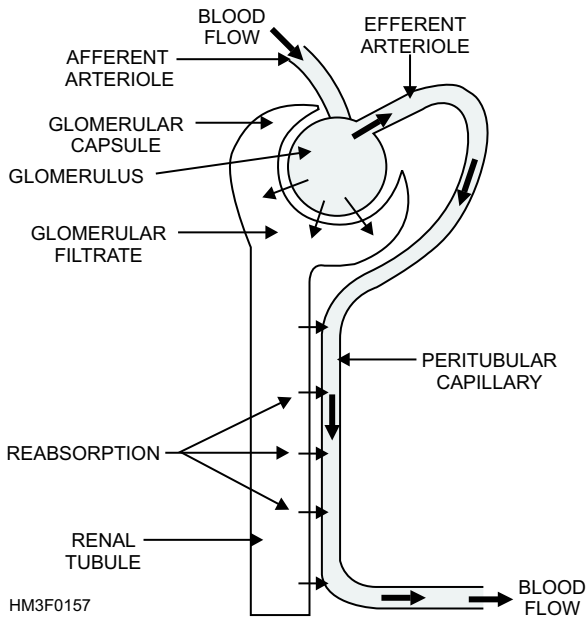


Figure 1-57.—The reabsorption process.

cortex to form a **collecting duct**. The collecting duct begins to merge within the renal medulla. The collecting ducts become increasingly larger as they are joined by other collecting ducts. The resulting tube is called the **papillary duct**. The papillary duct empties into the minor calyx through an opening in the renal papilla.

Function

The kidneys are effective blood purifiers and fluid balance regulators. In addition to maintaining a normal pH of the blood (acid-base balance), the kidneys keep the blood slightly alkaline by removing excess substances from the blood. The end product of these functions is the formation of **urine**, which is excreted from the body.

Urine is formed through a series of processes in the nephron. These processes are filtration, reabsorption, and secretion.

FILTRATION.—Urine formation begins when water and various dissolved substances are filtered out of blood plasma from a glomerular capillary into the glomerular capsule. The filtered substance (glomerular filtrate) leaves the glomerular capsule and enters the renal tubule.

REABSORPTION.—As glomerular filtrate passes through the renal tubule, some of the filtrate is reabsorbed into the blood of the **peritubular capillary** (fig. 1-57). The filtrate entering the peritubular capillary will repeat the filtration cycle. This process of reabsorption changes the composition of urine. For

instance, the filtrate entering the renal tubule is high in sugar content, but because of the reabsorption process, urine secreted from the body does not contain sugar.

SECRETION.—Secretion is the process by which the peritubular capillary transports certain substances directly into the fluid of the renal tubule (fig. 1-58). These substances are transported by similar mechanisms as used in the reabsorption process, but done in reverse. For example, certain organic compounds, such as penicillin and histamine, are secreted directly from the proximal convoluted tubule to the renal tubule. Also, large quantities of hydrogen ions are secreted in this same manner. The secretion of hydrogen ions plays an important role in regulating pH of body fluids.

The glomerulus filters gallons of blood each day. It is estimated that 2,500 gallons of blood pass through the kidneys in 24 hours, and about 80 gallons of glomerular filtrate. All the water from this filtrate is reabsorbed in the renal tubules except that containing the concentrated waste products.

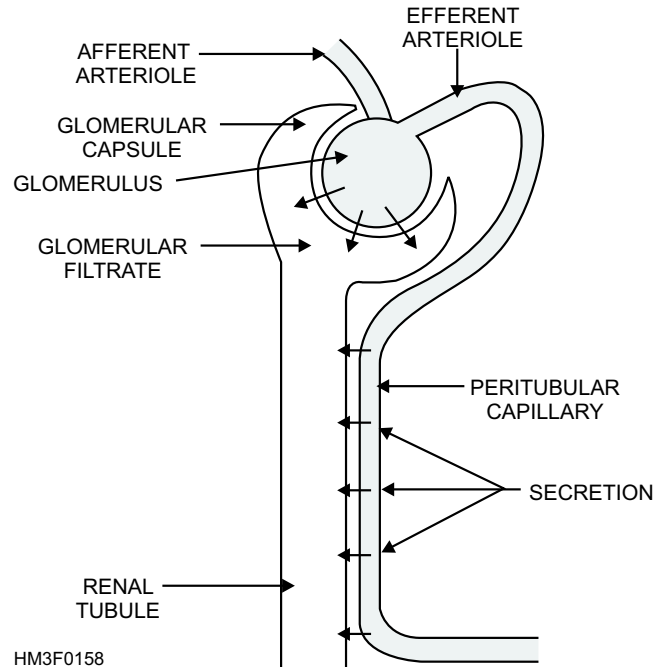


Figure 1-58.—The secretion process.

The average amount of urine an adult excretes varies from 1,000 to 1,500 ml per day. However, the amount of urine excreted varies greatly with temperature, water intake, and state of health. No matter how much water one drinks, the blood will always remain at a constant concentration, and the excess water will be excreted by the kidneys. A large water intake does not put a strain on the kidneys. Instead it eases the load of concentration placed on the kidneys.

URETERS

The ureters' only function is to carry urine from each kidney to the urinary bladder. The ureters are two membranous tubes 1 mm to 1 cm in diameter and about 25 cm in length. Urine is transported through the ureters by peristaltic waves (produced by the ureter's muscular walls).

URINARY BLADDER

The urinary bladder functions as a temporary reservoir for urine. The bladder possesses features that enable urine to enter, be stored, and later be released for evacuation from the body.

Structure

The bladder is a hollow, expandable, muscular organ located in the pelvic girdle (fig. 1-59). Although the shape of the bladder is spherical, its shape is altered by the pressures of surrounding organs. When it is empty, the inner walls of the bladder form folds. But as the bladder fills with urine, the walls become smoother.

The internal floor of the bladder includes a triangular area called the **trigone** (fig. 1-59). The trigone has three openings at each of its angles. The ureters are attached to the two posterior openings. The anterior opening, at the apex of the trigone, contains a funnel-like continuation called the **neck** of the bladder. The neck leads to the urethra.

The wall of the bladder consists of four bundles of smooth muscle fibers. These muscle fibers, interlaced, form the **detrusor muscle** (which surrounds the bladder neck) and comprise what is called the **internal urethral sphincter**. The internal urethral sphincter prevents urine from escaping the bladder until the pressure inside the bladder reaches a certain level. Parasympathetic nerve fibers in the detrusor muscle function in the micturition (urination) process. The

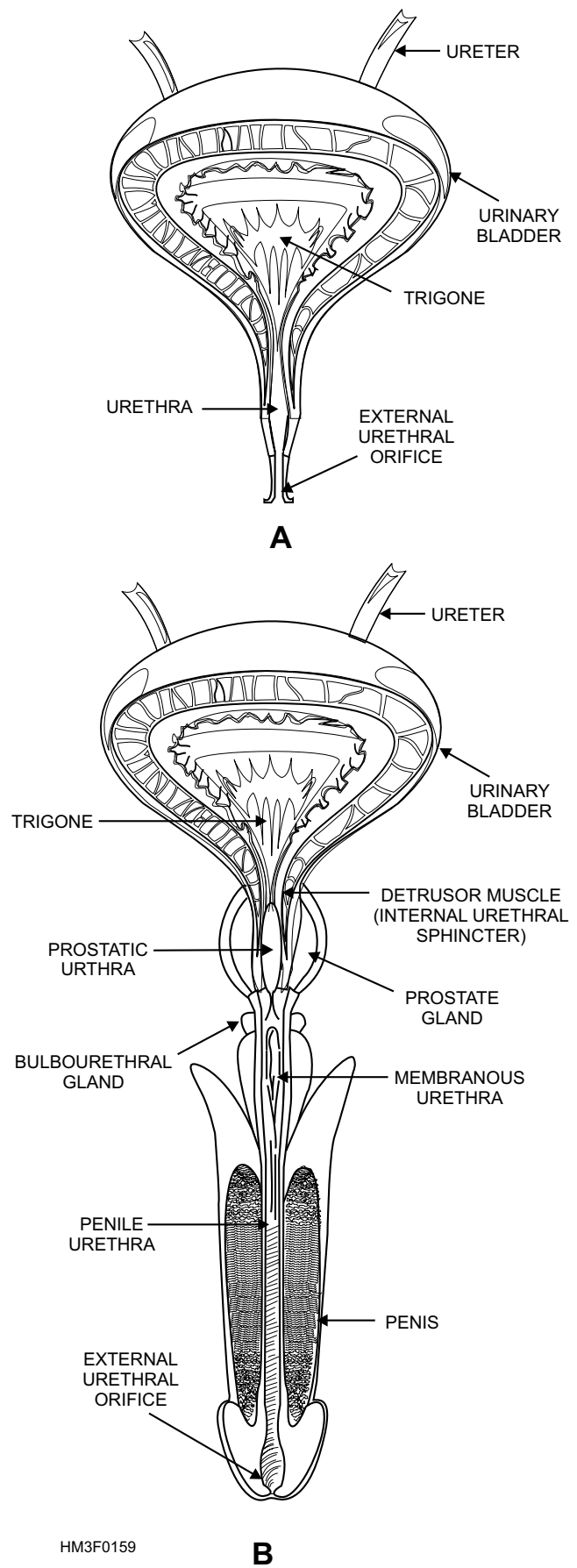


Figure 1-59.—Urinary bladder and urethra:
A. Frontal section of the female urinary bladder and urethra;
B. Frontal section of the male urinary bladder and urethra.

outer layer (**serous coat**) of the bladder wall consists of two types of tissue, **parietal peritoneum** and **fibrous connective tissue**.

Micturition (Urination)

Micturition is the process by which urine is expelled from the bladder. It involves the contraction of the detrusor muscle, and pressure from surrounding structures. Urination also involves the relaxation of the **external urethral sphincter**. The external urethral sphincter surrounds the urethra about 3 centimeters from the bladder, and is composed of voluntary muscular tissue.

Urination is usually stimulated by the distention of the bladder as it fills with urine. When the walls of the bladder contract, nerve receptors are stimulated, and the urination reflex is triggered. The urination reflex causes the internal urethral sphincter to open and the external urethral sphincter to relax. This relaxation allows the bladder to empty. The bladder can hold up to 600 ml of urine. The desire to urinate may not occur until the bladder contains 250-300 ml.

URETHRA

The urethra is the tube that carries urine from the bladder to the outside of the body (fig. 1-59, views A and B). The **urinary meatus** is the external urethral orifice. In the male, the urethra is common to the urinary and reproductive systems; in the female, it belongs only to the urinary system.

Female Urethra

The female urethra is about 4 cm long, extending from the bladder to the external orifice, (fig. 1-59, view A).

Male Urethra

The male urethra is about 20 cm long and is divided into three parts: the prostatic, membranous, and penile portions. See view B of figure 1-59 for an illustration of the male urethra.

PROSTATIC URETHRA.—The prostatic urethra is surrounded by the prostate gland; it contains the orifices of the prostatic and ejaculatory ducts. This portion of the male urethra is about 2.5 cm long.

MEMBRANOUS URETHRA.—The membranous urethra is about 2 cm in length and is surrounded by the external urethral sphincter.

PENILE URETHRA.—The penile urethra, the longest portion, is about 15 cm long. It lies in the ventral portion of the penis. The urethra terminates with the external orifice at the tip of the penis.

MALE REPRODUCTIVE SYSTEM

LEARNING OBJECTIVE: *Recall the parts of the male reproductive system and their function(s).*

The organs of the male and female reproductive systems are concerned with the process of reproducing offspring, and each organ is adapted to perform specialized tasks. The primary male sex organs of the reproductive system are the testes. The other structures of the male reproductive system are termed accessory reproductive organs. The accessory organs include both internal and external reproductive organs. See figure 1-60 for an illustration of the male reproductive system.

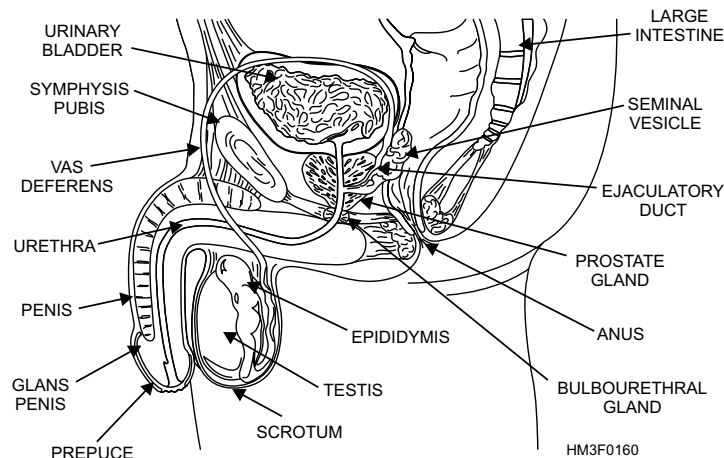


Figure 1-60.—The male reproductive system.

TESTES

The testes, as stated earlier, are the primary male reproductive organs. They produce sperm cells (spermatozoa) and male hormones, both necessary for reproduction.

Structure

The testes are oval glands suspended inside a sac (the scrotum) by a **spermatic cord**. The spermatic cords are formed by the vas deferens, arteries, veins, lymphatics, and nerves, all bound together by connective tissue.

Each testis is encapsulated by a tough, white, fibrous tissue called the tunica albuginea. The interior of the testis is divided into 250 lobules (small lobes). Each lobule contains 1 to 4 highly coiled, convoluted tubules called **seminiferous tubules**. These tubules unite to form a complex network of channels called the **rete testis**. The rete testis give rise to several ducts that join a tube called the **epididymis** (fig. 1-60).

Functions

The testes perform two functions: to produce sperm cells and to secrete male sex hormones. The process by which sperm cells are produced is called **spermatogenesis**. Spermatogenesis occurs in the seminiferous tubules of the testes. Once the sperm cells are formed, they collect in the lumen of each seminiferous tubule. When the sperm cells are ready, they pass through the rete testis to the epididymis, where they remain for a time to mature. The production of sperm cells occurs continually throughout the reproductive life of a male.

The male hormone **testosterone** is produced in the testes. This hormone is initially responsible for the formation of the male reproductive organs. During puberty, testosterone stimulates the enlargement of the testes and various other accessory reproductive organs. It also causes the development of the male secondary sexual characteristics. Refer to the section titled “The Endocrine System” for more detailed discussion on male secondary sexual characteristics.

Other actions of testosterone include increasing the production of red blood cells. As a result, the average number of red blood cells in blood is usually greater in males than in females.

INTERNAL ACCESSORY ORGANS

The internal accessory organs of the male reproductive system include the epididymis, vas deferens, ejaculatory ducts, seminal vesicle, urethra, prostate gland, bulbourethral glands, and semen (fig. 1-60).

Epididymis

Each epididymis is a tightly coiled, thread-like tube that is approximately 6 meters long. This tube is connected to the ducts within the testis. The epididymis covers the top of the testis, runs down the testis' posterior surface, and then courses upward to form the vas deferens.

The epididymis secretes the hormone glycogen, which helps sustain the lives of stored sperm cells and promotes their maturation. When immature sperm cells enter the epididymis, they are not mobile. However, as the sperm cells travel through the epididymis, they mature and become mobile. Once the sperm cells are mature, they leave the epididymis and enter the vas deferens.

Vas Deferens

The vas deferens is a small tube that connects the epididymis and ejaculatory duct. It ascends as part of the spermatic cord through the inguinal canal of the lower abdominal wall into the pelvic cavity, and transmits the sperm to the ejaculatory ducts.

Ejaculatory Ducts

The vas deferens and the seminal vesicles converge, just before the entrance of the prostate gland, to form the ejaculatory ducts (fig. 1-60). The ejaculatory ducts open into the prostatic urethra. Its function is to convey sperm cells to the urethra.

Seminal Vesicles

The seminal vesicles are two pouches that are attached to the vas deferens near the base of the urinary bladder. The lining of the inner walls of the seminal vesicles secrete a slightly alkaline fluid. This fluid is thought to help regulate the pH of the tubular contents as sperm cells are conveyed to the outside. The secretion produced by the seminal vesicles also contains a variety of nutrients, such as fructose (simple sugar), that provides the sperm cells an energy source.

At the time of ejaculation, the contents of the seminal vesicles are emptied into the ejaculatory ducts. This action greatly increases the volume of fluid that is discharged by the vas deferens.

Urethra

The urethra is an important organ of both the urinary and reproductive systems. The role of the urethra, in the reproductive system, is to transport sperm through the penis to outside the body. See “The Urinary System” section for information on the structure of the urethra.

Prostate Gland

The prostate gland, made of smooth muscle and glandular tissue, surrounds the first part of the urethra. It resembles a chestnut in shape and size, and secretes an alkaline fluid to keep the sperm mobile, protecting it from the acid secretions of the female vagina. This substance is discharged into the urethra as part of the ejaculate, or semen, during the sexual act.

Bulbourethral Glands

Bulbourethral glands, also known as **Cowper's glands**, are two pea-sized bodies located below the prostate gland and lateral to the membranous urethra. These glands are enclosed by fibers of the external urethral sphincter. They release a mucous-like fluid in response to sexual stimulation and provide lubrication to the end of the penis in preparation for sexual intercourse.

Semen

Semen is composed of sperm and secretions from the seminal vesicles, prostate, and bulbourethral glands. It is discharged as the ejaculate during sexual intercourse. There are millions of sperm cells in the semen of each ejaculation, but only one is needed to fertilize the ovum. It is generally considered that fertilization of the ovum occurs while it is still in the fallopian tubes. Therefore, it is apparent that sperm cells can move actively in the seminal fluid deposited in the vagina and through the layers of the secretion lining the uterus and fallopian tubes.

EXTERNAL ACCESSORY ORGANS

The external accessory organs of the male reproductive system include the scrotum and penis (fig. 1-60).

Scrotum

The scrotum is a cutaneous pouch containing the testes and part of the spermatic cord. Immediately beneath the skin is a thin layer of muscular fibers (the cremaster), which is controlled by temperature and contracts or relaxes to lower or raise the testes in relation to the body. This muscular activity of the scrotum is necessary to regulate the temperature of the testes, which is important in the maturation of sperm cells.

Penis

The penis is a cylindrical organ that conveys urine and semen through the urethra to the outside. The penis is composed of three columns of spongy cavernous tissue, bound together by connective tissue and loosely covered by a layer of skin. Two of the columns, the **corpora cavernosa**, lie superiorly side by side; the third column, the **corpus spongiosum**, lies below the other two columns. The urethra is located in the corpus spongiosum. The dilated distal end of the corpus spongiosum is known as the **glans penis** (fig. 1-60). The urethra terminates at the glans penis.

The cavernous tissue becomes greatly distended with blood during sexual excitement, causing an erection of the penis. The loose skin of the penis folds back on itself at the distal end (forming the **prepuce**, or foreskin) and covers the glans. The prepuce is sometimes removed by a surgical procedure called a **circumcision**.

FEMALE REPRODUCTIVE SYSTEM

LEARNING OBJECTIVE: *Recall the parts of the female reproductive system and their function(s).*

The organs of the female reproductive system are specialized to produce and maintain the female sex cells, or egg cells; to transport these cells to the site of fertilization; to provide an environment for a developing offspring; to move the offspring outside; and to produce female sex hormones. The primary female reproductive organs are the ovaries. The other structures of the female reproductive system are considered accessory reproductive organs. The

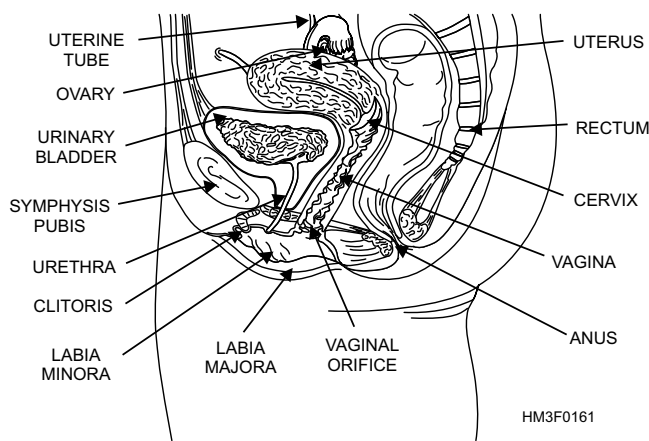


Figure 1-61.—The female reproductive system.

accessory organs include both internal and external reproductive organs (fig. 1-61).

OVARIES

The ovaries, as stated earlier, are the primary female reproductive organs, producing the female sex cells and sex hormones (fig. 1-61).

Structure

The ovaries, or female gonads, are two almond-shaped glands suspended by ligaments in the upper pelvic cavity. There is one ovary on each side of the uterus. The ligaments that suspend the ovaries contain ovarian blood vessels and nerves.

The tissues of an ovary are divided into two regions, an inner **medulla** and an outer **cortex**. The ovarian medulla is largely composed of loose connective tissue, numerous blood vessels, lymph vessels, and nerves. The ovarian cortex is composed of compact tissue containing tiny masses of cells called **ovarian (primordial) follicles**. The follicles contain the female sex cells or **ova**. The external surface of the ovary is covered by a layer of cuboidal epithelium cells. Beneath the epithelium is a layer of dense connective tissue.

Primordial Follicle

In the outer region of the ovarian cortex, microscopic groups of cells are referred to as primordial follicles. The primordial follicles consist of a single large cell, called an **oocyte**, which is surrounded by a layer of flattened epithelial cells called **follicular cells**. The oocyte is an immature egg

cell. Follicular cells surround a developing egg cell and secrete female sex hormones. There are approximately 400,000 primordial follicles at puberty. Of these, probably fewer than 500 will be released from the ovary during the reproductive life of a female.

At puberty, the anterior pituitary gland secretes increased amounts of FSH (follicle-stimulating hormone). In response, the ovaries enlarge and many of the primordial follicles begin to mature. During this maturation process, the oocyte enlarges and the follicle cells multiply until there are 6 to 12 layers. Fluid-filled spaces begin to appear among the follicle cells. These spaces join to form a single cavity called the antrum. Ten to fourteen days after this process begins, the primordial follicle reaches maturity. The mature primordial follicle (preovulatory or graafian follicle) and its fluid-filled cavity bulges outward on the surface of the ovary, like a blister.

Ovulation

Ovulation is the process by which the mature oocyte is released from the primordial follicle (fig. 1-62). Ovulation is stimulated by hormones from the anterior pituitary gland. These hormones cause the mature follicle to swell rapidly and its walls to weaken. Eventually the wall ruptures, permitting the oocyte and 1 or 2 layers of follicle cells to be released from the ovary's surface.

After ovulation, the oocyte is usually propelled to the opening of a nearby fallopian tube. If the oocyte is not fertilized by a sperm cell within a relatively short time, it will degenerate.

This process of ovulation occurs once a month. Each ovary normally releases an ovum every 56 days. The right and left ovary alternately discharge an ovum approximately every 28 days. The menstrual cycle in most women is therefore approximately 28 days.

Female Sex Hormones

Female sex hormones are produced by the ovaries and various other tissues, such as the adrenal glands, pituitary gland, and placenta (during pregnancy). These female sex hormones are **estrogen** and **progesterone**.

The primary source for estrogen is the ovaries. At puberty, estrogen stimulates enlargement of various accessory organs, which include the vagina, uterus, fallopian tubes, and external structures. Estrogen is also responsible for the development and maintenance

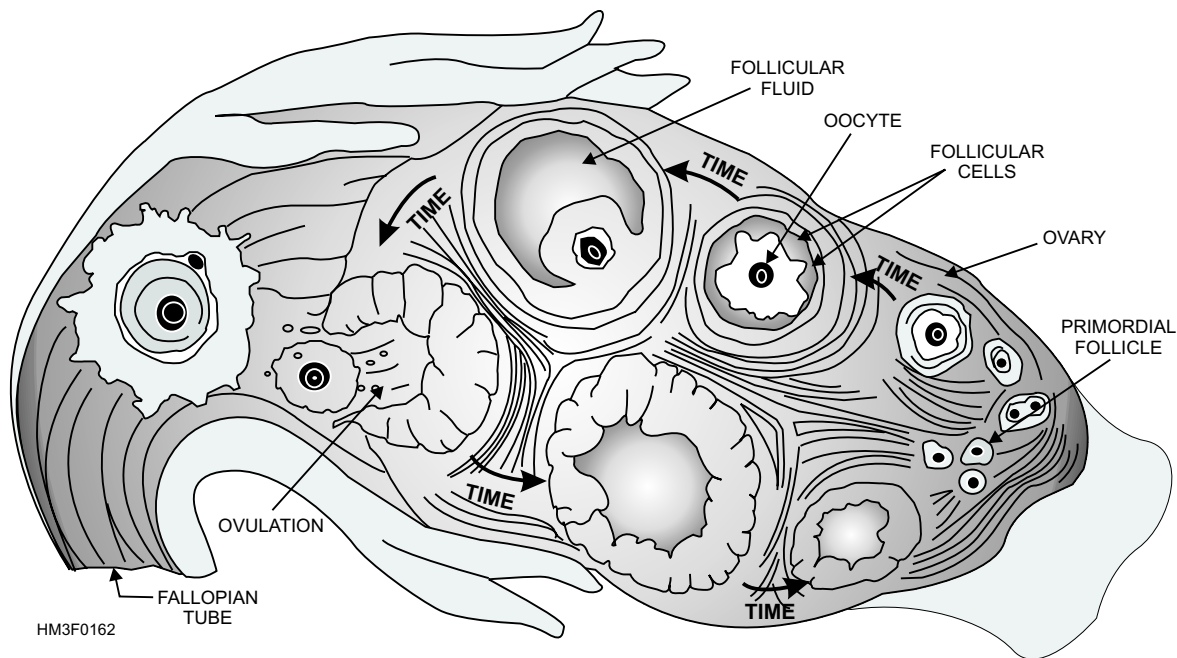


Figure 1-62.—Ovulation process.

of female secondary sexual characteristics. See section titled “Endocrine System” for listing of secondary female sexual characteristics.

The ovaries are also the primary source of progesterone (in a nonpregnant female). This hormone promotes changes that occur in the uterus during the female reproductive cycle. In addition, progesterone stimulates the enlargement of mammary glands and ducts, and increases fat deposits in female breasts during puberty.

INTERNAL ACCESSORY ORGANS

The internal accessory organs of the female reproductive system include a pair of fallopian tubes, the uterus, and the vagina (fig. 1-61).

Fallopian Tubes

The fallopian tubes, also known as uterine tubes, serve as ducts for the ovaries, providing a passageway to the uterus. The fallopian tubes are composed of three tissue layers. These tissue layers include an inner mucosal layer, a middle muscular layer, and an outer serous layer, and they are continuous with the layers of the uterus. The fallopian tubes are in contact with the ovaries but are not continuous with them. Their funnel-shaped openings, called **free openings**, are fringed with fingerlike processes that pick up an ovum and draw it into the fallopian tubes. Once the ovum enters the fallopian tubes, it is transported to the uterus

by peristalsis and gravity. Fertilization of an ovum normally takes place in the fallopian tubes.

Uterus

The function of the uterus is to receive the embryo that results from the fertilization of an egg cell, and to sustain its life during development. The uterus, or womb, is a hollow, pear-shaped organ with thick, muscular walls. The uterus is divided into two main regions, the **body** and **cervix** (fig. 1-61). The body of the uterus consists of the upper two-thirds of the uterus. The cervix is the lower one-third portion of the uterus that projects into the upper part of the vagina. The cervical opening into the vagina is called the **external os**.

The uterine wall is composed of three layers: the endometrium, the myometrium, and the perimetrium. The inner lining consists of specialized epithelium, called **endometrium**, which undergoes partial destruction approximately every 28 days in the nonpregnant female. The middle layer, the **myometrium**, consists of bundles of interlaced muscular fibers. The muscular layer produces powerful rhythmic contractions that are important in the expulsion of the fetus at birth. The **perimetrium** consists of an outer serosal layer that covers the body of the uterus and part of the cervix. The uterus also has three openings: superiorly and laterally, two openings connect the fallopian tubes to the uterus, and inferiorly, an opening leading to the vagina.

Vagina

The vagina is the organ that receives the male sperm during intercourse. It also forms the lower portion of the birth canal, stretching widely during delivery. In addition, it serves as an excretory duct for uterine secretions and menstrual flow.

The vagina is a fibromuscular tube capable of great distention. The canal is approximately 9 cm long and extends from the uterus to the outside. The vaginal orifice is partially closed by a thin membrane of tissue called the **hymen**. The wall of the vagina consists of three layers. The inner **mucosal layer** does not have mucous glands; the mucous found in the vagina comes from the glands of the cervix. The middle **muscular layer** consists mainly of smooth muscle fibers. At the lower end of the vagina is a thin band of smooth muscle that helps close the vaginal opening. The outer **fibrous layer** consists of dense fibrous connective tissue interlaced with elastic fibers. These fibers attach the vagina to the surrounding organs.

EXTERNAL ACCESSORY ORGANS

Many of the external accessory organs of the female reproductive system are referred to collectively as the **vulva**. The vulva includes the labia majora, the labia minora, the clitoris, and the vestibular glands (fig. 1-63). The mammary glands are also considered an accessory organ of the female reproductive system.

Labia Majora

The function of the labia majora is to enclose and protect the other external reproductive organs. The labia majora are composed of two round folds of fat tissue and a thin layer of smooth muscle, covered by skin. On the outer portion of the labia majora, the skin has numerous hairs, sweat glands, and sebaceous glands. The inner portion of skin is thin and hairless. The labia majora extend from the mons pubis anteriorly to the perineum (the region between the vaginal orifice and the anus). The **mons pubis** is the pad of fatty tissue beneath the skin, which overlies the symphysis pubis.

Labia Minora

Within the labia majora folds are two smaller folds, called the labia minora. The labia minora extend from the clitoris to either side of the vaginal orifice.

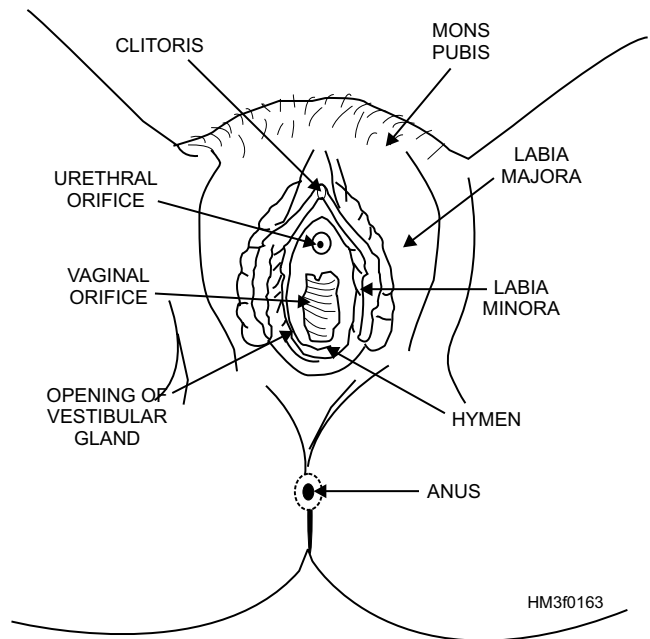


Figure 1-63.—External reproductive organs.

Clitoris

The clitoris is a small projectile at the anterior end of the vulva between the labia minora. It is richly endowed with sensory nerves that are associated with the feeling of pleasure during sexual stimulation.

Vestibule

The vestibule is the area enclosed by the labia minora that includes that vaginal and urethral openings. The vestibule contains a pair of vestibular glands, more commonly known as the **Bartholin's glands**. The Bartholin's glands lay on each side of the vaginal opening. The ducts of these glands secrete fluid that moistens and lubricates the vestibule.

Mammary Glands

The mammary glands, or breasts, are accessory organs of the female reproductive system. They develop during puberty under the influence of the hormones estrogen and progesterone. The breasts are responsible for the secretion of milk (**lactation**) for the nourishment of newborn infants.

Structurally, the breasts resemble sweat glands. At the center is a nipple containing 15 to 20 depressions into which ducts from the lobes of the gland empty. During pregnancy, placental estrogen and progesterone stimulate further development of the mammary glands

in preparation for lactation. After childbirth, hormones secreted by the anterior lobe of the pituitary gland stimulate production for 6 to 9 months.

FEMALE REPRODUCTIVE CYCLE

Females around age 11 begin to experience the female reproductive cycle and continue into middle age, after which it ceases. The female reproductive cycle, or menstrual cycle, is characterized by regular, recurring changes in the uterine lining, resulting in menstrual bleeding (**menses**). The first phase of the recurring reproductive cycle is menstrual bleeding. Menstrual bleeding begins when the endometrial lining starts to slough off from the walls of the uterus, and it is characterized by bleeding from the vagina. This is day 1 of the cycle, and this phase usually lasts through day 5. The time between the last day of the menses and ovulation is known as the postmenstrual phase. It lasts from day 6 through day 13 or 14 and is characterized by proliferation of endometrial cells in the uterus, which develop under the influence of the hormone estrogen. Ovulation, as discussed earlier in this section, is the rupture of a primordial follicle with the release of a mature ovum into the fallopian tubes. It usually occurs on day 14 or 15 of the cycle. The postovulatory (premenstrual) phase is the time

between ovulation and the onset of the menstrual bleeding and normally lasts 14 days. During this phase the ovum travels through the fallopian tubes to the uterus. If the ovum becomes fertilized during this passage, it will become implanted in and nurtured by the newly developed endometrial lining. However, if fertilization does not take place, the lining deteriorates and eventually sloughs off, marking day 1 of the next cycle.

SUMMARY

In this chapter, you have learned about the basic structures of the cell to the many complex systems of the human body. In addition, you have acquired the understanding of how each body system functions and how each system is interdependent upon each other. You will use this knowledge of human anatomy and physiology throughout your career in the medical services. For example, the anatomical terminology will be used in describing location of injuries or conditions. Also, when you perform patient assessments, a clear and thorough understanding of anatomy and physiology is essential. Patient assessment and documentation procedures will be discussed in the next chapter, entitled “Fundamentals of Patient Care.”

